

Short Communication

IMPLICATION OF PHYTOTHERAPEUTIC SOURCES FOR POTENTIAL EPITHELIAL WOUND HEALING ABILITY:A NOVEL-HERBAL APPROACH

J. Maryam*, R. Arif., Z. Mehmood, A. Nadeem and S. Ali

Institute of Biochemistry and Biotechnology, University of Veterinary and Animal Sciences, Lahore, Pakistan

Corresponding Author's Email: maryam.javed@uvas.edu.pk

ABSTRACT

The remedy of epithelial lesions has been a crucial subject of different studies. Natural herbal products play a vital role as compatible therapeutic sources. Aloe Vera gel has powerful effects on wounds, specifically cutaneous abrasion healing. In current study, we examined the effect of Aloe Vera gel on dermal wound allay and found out that Aloe Vera improves the wound healing by reducing the cutaneous inflammation. As additional effect, it is also useful in hair growth. This research was conducted in Albino Rats. Mycitracin in the form of ointment was applied for evaluating the lesion allay ability in the incision wound model as comparative medicine. The results illustrated the lesion contraction as well as reduction in the inflammation which firmly supports the healing properties of Aloe Vera.

Key words: Aloe Vera, Wound Healing, Inflammation, Mycitracin, Lesion.

<https://doi.org/10.36899/JAPS.2020.2.0052>

Published online March 02, 2020

INTRODUCTION

Epithelial wounds cause distress and inconvenience, if not treated well in time. Few maladies like diabetes, immunocompromised conditions, ischemia, malnourishment, neighborhood contamination and nearby tissue harm may regularly prompt delay in wound recuperating. Wound healing is a complex natural process, where the fundamental objective of clinical intercession is the advancement of tissue reclamation (Velnar *et al.*, 2009; Pastar *et al.*, 2014; Takzare *et al.*, 2009). This incorporates three periods of thrombosis and irritation, expansion and arrangement of new tissue, and tissue recovery (Werner *et al.*, 2007; Oryan *et al.*, 2016). The Aloe Vera plant has been known and utilized for a considerable length of time for its wellbeing, excellence, restorative and healthy skin properties (Boudreau and Beland 2006). Various animal studies exhibit that Aloe Vera diminishes consuming, tingling, and scarring related to radiation dermatitis. Aloe Vera was additionally found to quicken mending of perpetual leg ulcers, surgically initiated wounds, and frostbite. Salicylic Acid present in Aloe Vera contributes in pain relieving and calming by restraining prostaglandin generation (Sanchez-Machado *et al.*, 2017). Magnesium lactate is likewise present in Aloe Vera and is believed to be antipyretic by restraining histidine decarboxylase, which controls the change of histidine to histamine in pole cells (Surjushe *et al.*, 2008; Choi *et al.*, 2001; Chithra *et al.*, 1998; Moriyama *et al.*, 2016). Current study was planned to evaluate the effect of Aloe Vera Gel on the epithelia lesion induced by incision to optimize the time period for application.

MATERIALS AND METHODS

Experimental Taxnomic Specie: The specie that was used in the current research were Sprague-Dawley Albino rats. The weight of the albino rats was, approximately around 30 grams each. The research work was performed at the Animal Center at the University of Veterinary and Animal Sciences, Lahore. Clinical trial was performed after thorough approval of University Research Ethical Committee (DR410-08/05/17).

Sedation and Incision: The sedative that was used for the research, to induce the incision was *Chloroform*. A 3.5% *chloroform solution*, at a dose of 0.35 mg/g body weight was given to the rats. This kind of sedative hampers any movement of the specie for at least for 20-25 minutes after the administration of the anesthetic solution. For the purpose of an incision the dorsal hair of the rats were shaved off by razors (5/8 inches) by following the sterilization protocols. Eight albino rats were selected irrespective of their gender. Then dorsal incisions (2mm) were made in a highly standardized environment, keeping the ethical concerns in mind.

Ointment Preparation for Topical Application: *A: Aloe Vera Gel Preparation:* A fresh leaf of Aloe Vera was taken and the slimy gel was extracted. The Aloe gel was extracted fresh everyday before the topical application. Afterwards, when the gel was extracted, it was mixed well till it was turned into a homogenous mixture.

B: Mycitracin Ointment: The pharmaceutical ointment that was used on a certain group of albino rats was *Mycitracin* for comparative effects. The medication was

applied everyday after removing the pre-existing medicine with the help of a clean cotton swab.

Experimental Design: After the wound creation, the albino rats were divided into two groups, both of which consisting of four albino rats in each. *Group A:* Albino rats treated with Aloe Vera Gel. *Group B:* Albino Rats treated with Mycitracin. The dynamic changes in wound constriction were observed planimetrically by following the injury edge on a clean graph paper each substitute day without making any harm the region of injury. Drug dosage was considered on the base of wound size. All edges of the wounds were topically covered with medicine.

Statistical Analysis: The estimation of lesion reduction against the number of days taken was made by graphical representation shown in Fig-2. The rate of wound withdrawal and the time of epithelization was figured and communicated as the rate lessening of unique injury measures. The time of epithelization of the injury was communicated as the quantity of days taken for finish epithelization.

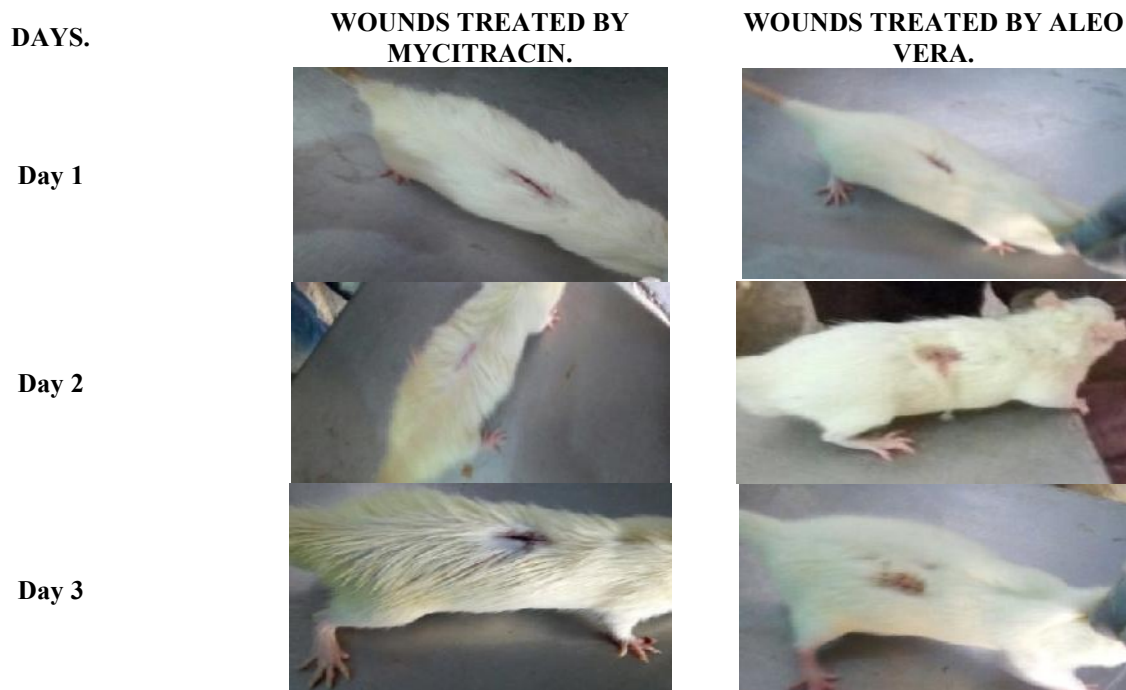RESULTS AND DISSCUSSION

Current study evaluated the anti-inflammatory activity of Aloe Vera gel on an epithelial wound. Trial was conducted for the period of seven days. During the course of treatment with Aloe Vera, wound healing was evaluated for all signs of inflammation (Fig-1). The redness of the incisions was reduced in case of Aloe Vera

at day 4th day while for Mycitracin, redness took more days to subside. Reduction in the swelling was also early in case of Aloe Vera. Wound diameter was reduced in case of Aloe Vera at day 7th, while for Mycitracin, wound took more time to heal. There was also regrowth of hair at the end of the trail on incision site which were treated with Aloe Vera. The albino rats that were treated by Mycitracin also showcased a great progress, but still lacked the hair growth as well as the closed wound.

The results in the healing of wound supports topical Aloe Vera gel as a vital product for support in the recovery of cuts, lesions and even dermal ulcers, possibly due to a synergistic reaction between the biologically active substances found in the Aloe Vera Gel. Thus, it may be negotiated that the extract of Aloe Vera contains the properties to fullfill all the conditions, also it gives a surrounding at the surface of the scar in which healing occurs at the maximum level consistent with the production of granulation tissue with an adequate appearance.

Therefore, in the topical study, we observed the effect of Aloe Vera on dermal wound healing and found out that Aloe Vera enhances the scar healing and also other processes both rationally as well as experimentally. More studies are still required to validate the results. Aloe Vera treatment for the progress of wound healing is beneficial. So we can conclude that Aloe Vera was more effective in healing the wound and in subsiding signs of inflammation than commercial product. This can be a useful and economical herbal therapeutic source to treat the wounds and inflammation.



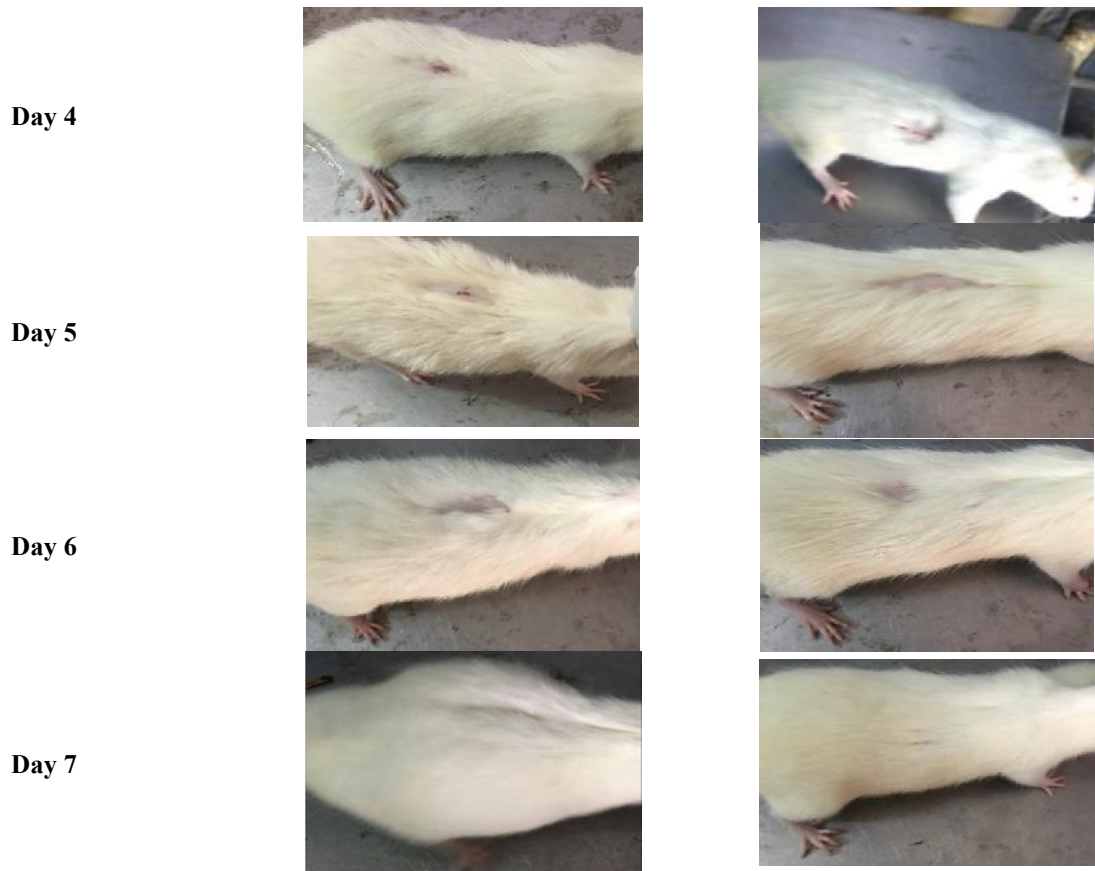

Fig-1:Comparitive Analysis between Aloe Vera and Mycitracin.

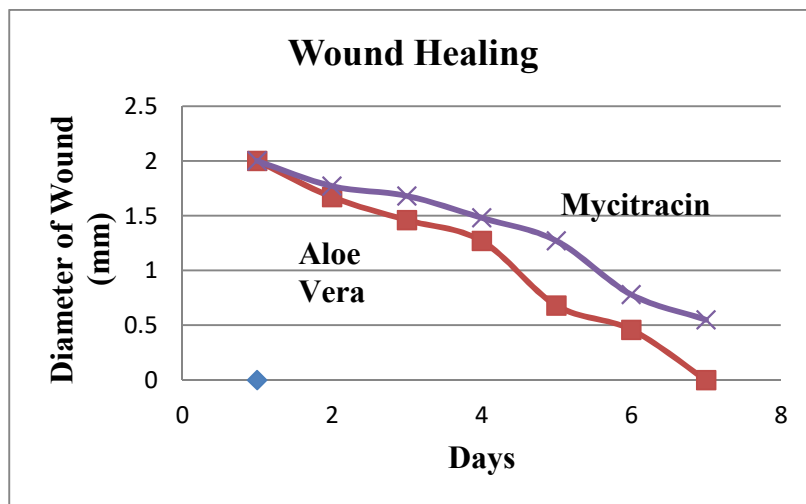


Fig 2. Graphical Representation of the contraction of wound by Aloe Vera and Mycitracin.

REFERENCES

Boudreau, M.D. and F.A. Beland (2006). An evaluation of the biological and toxicological properties of *Aloe barbadensis* (Miller), *Aloe vera*. J Environ Sci Health C Environ Carcinog Ecotoxicol Rev. 24(1): 103–154.

Chithra, P., G.B. Sajithlal, and G. Chandrakasa (1998). Influence of *Aloe vera* on collagen characteristics in healing dermal wounds in rats. Mol Cell Biochem. 181(1-2): 71–76.

Choi, S.W., B.W. Son, Y.S. Son, Y.I. Park, S.K. Lee, and M.H. Chung (2001). The wound-healing effect

- of a glycoprotein fraction isolated from *Aloe vera*. Br J Dermatol. 145(4): 535–545.
- Moriyama, M., H. Moriyama, and J. Uda (2016). Beneficial effects of the genus *Aloe* on wound healing, cell proliferation, and differentiation of epidermal keratinocytes. PLoS One. 11(10): e0164799.
- Oryan. A., A. Mohammadalipour., A. Moshiri, and M. R. Tabandeh (2016). Topical Application of Aloe vera Accelerated Wound Healing, Modeling, and Remodeling: An Experimental Study. Ann Plast Surg. 77(1): 37-46.
- Pastar, I., O. Stojadinovic, and N.C. Yin (2014). Epithelialization in wound healing: a comprehensive review. Adv Wound Care(New Rochelle). 3(7): 445–464.
- Sánchez-Machado, D.I., J.López-Cervantes, R. Sendón, and R. Sanches-Silva (2017). *Aloe vera*: ancient knowledge with new frontier. Trends Food Sci Tech. 61: 94–102.
- Surjushe, A., R. Vasani, and D.G. Saple (2008). *Aloe vera*: a short review. Indian J Dermatol. 53(4): 163–166.
- Takzare. N., M.J. Hosseini., G. Hasanzadeh., H. Mortazavi., A. Takzare, and P. Habibi (2009). Influence of Aloe Vera gel on dermal wound healing process in rat. Toxicol Mech Methods. 19(1): 73-7.
- Velnar, T., T. Bailey, and V.Smrkolj (2009). The wound healing process: an overview of the cellular and molecular mechanisms. J Int Med Res. 37(5): 1528–1542.
- Werner, S., T. Krieg, and H.Smola (2007). Keratinocyte-fibroblast interactions in wound healing. J Invest Dermatol. 127(5): 998–1008.