EFFECT OF *Syzygium aromaticum* EXTRACT AND CLOMIPHENE CITRATE ON ESTROUS CYCLE CHARACTERISTICS AND OVARIAN HISTOLOGY IN FEMALE WISTAR RATS

M. O. O. Attah [1,2], H. I. Bedan [1], D. J. Abana [1] and N. I. Dibal [1]

[1]Departmant of Human Anatomy, Faculty of Basic Medical Sciences, University of Maiduguri, Borno State, Nigeria
[2]Departmant of Human Anatomy, Faculty of Medicine, Cyprus International University, Nicosia, Cyprus.
* Corresponding author's Email: mattah@ciu.edu.tr

ABSTRACT

This study investigated the effects of *Syzygium aromaticum* (*S. aromaticum*) extract on estrous-cycle duration and ovarian histomorphology in female Wistar rats, in comparison with clomiphene citrate (CC). Twenty adult female rats were randomly assigned into four groups: control, CC-treated (50 mg/kg), low-dose extract (200 mg/kg), and high-dose extract (400 mg/kg). Treatments were administered orally for 21 days. Estrous-cycle stages were monitored daily using vaginal cytology, while ovarian tissues were harvested and processed for histological examination at the end of the experiment. Administration of *S. aromaticum* significantly ($p<0.05$) altered the duration of several estrous-cycle phases, including prolongation of proestrous and changes in the durations of estrous, metestrous, and diestrous compared with the control and clomiphene-treated groups. Qualitative histological examination revealed ovarian follicles at different developmental stages, including secondary, tertiary, and Graafian follicles, in the extract-treated groups. CC-treated ovaries showed prominent primary follicles, with less evident mature follicles and corpora lutea. Overall, *S. aromaticum* extract altered estrous-cycle dynamics and was associated with qualitative changes in ovarian histomorphology. However, because follicular structures were not quantitatively assessed and hormonal concentrations, ovulation, and fertility outcomes were not determined, these findings should not be interpreted as evidence of enhanced folliculogenesis or improved reproductive function. Further studies incorporating quantitative follicular assessment, hormonal profiling, and reproductive outcomes are warranted.

Keywords: *Syzygium aromaticum*, Ovary, Estrous Cycle, Ovarian Follicles, Clomiphene Citrate

This article is an open access article distributed under the terms and conditions of the Creative Commons Attribution (CC BY) license (https://creativecommons.org/licenses/by/4.0

Received April 28, 2026 Published Online October 21, 2026 https://doi.org/10.36899/JAPS.2027.1.0009

INTRODUCTION

The estrous cycle in rodents is a highly synchronized reproductive cycle which consists of four distinct stages – proestrous, estrous, metestrous and diestrous (Caligioni, 2023, Sanabria *et al.*,2019). The rodent estrous cycle modulates a range of biological functions, from gene expression to behavior (Alvord and Pendergrass, 2024). The cycle is characterized by distinct hormone concentration profiles. Determination of the estrous cycle is vital for maximizing reproductive efficiency which is essential for timed pregnancies, advancing biomedical research, and ensuring animal welfare. Accurately identifying the stage of the cycle allows for precise control over breeding and experimental timing, significantly reducing variability in research data (Belozertseva *et al.*,2024). The short and precise length of estrous cycle in rodents makes them very suitable for use in the investigation of the effects of drugs and chemicals on reproductive function.

Given the difficulty of repeatedly sampling plasma steroid hormones from rodents, the primary method for classifying estrous stage in rodents is by identifying vaginal epithelial cell types (Wolcott *et al.*,2022). The procedure for obtaining a vaginal smear is relatively non-invasive and animals can become readily accustomed to the process of obtaining the smears. Few materials are required for this process and assessments of the cells can be easily performed (Quignon, 2024). When incorporated as an adjunct to other endpoint measures, determination of a female's cycling status can contribute important information about the nature of a toxicant insult to the reproductive system (Cora *et al.*,2015). Comparing the effect of other substances on the estrous cycle can help to provide more comprehensive mechanistic portrait of the effect of the substance and may provide some indication of a toxicant's impact on human or rodent reproductive physiology (Goldman *et al.*,2007, Ajayi and Akhigbe, 2020). Assessment of vaginal cytology in regularly cycling animals

also provides a means to establish a comparable endocrine milieu for animals at necropsy (Goldman *et al.*,2007, Alvord and Pendergrass, 2024).

Clomiphene citrate (CC) is prescribed as an oral prescription used to induce ovulation and regulate the ovulation cycle. It acts as a selective estrogen receptor modulator (SERM), it signals the pituitary gland to release essential hormones (follicle stimulating hormone (FSH) and luteinizing hormone (LH)) to stimulate egg development (Mbi-Feh and Wadhwa, 2020). It has been found in many studies to increase the number of follicles (Chaube *et al.*,2014). In polycystic ovarian syndrome rat models, CC has been shown to reduce excessive ovarian weight, regulate the ovarian cycle and improve ovulation disorders by adjusting metabolic pathways and serum hormone levels (Kessel and Hsueh, 1987). However, studies show that CC has cytogenic and genotoxic properties. It has also been found to have an antiestrogenic effect and has been found to cause endothelial thinning (Chaube *et al.*,2014, Kessel and Hsueh, 2018). Long term use in animal studies have shown structural malformations and embryo fetal loss (Yilmaz *et al.*,2017). There is therefore a need to find a complementary alternative that has a protective and stimulating effect on the reproductive system without the deleterious effects. *S. aromaticum* has been used for centuries in various local and traditional medicine systems—notably Ayurvedic, Unani, and Persian medicine—for reproductive, sexual, and gynecological purposes, many of these uses are rooted in folklore.

The active biocomponents of *S. aromaticum* are primarily phenylpropanoids including eugenol which is responsible for the plant's anesthetic, antiseptic and antioxidant properties. Eugenyl acetate acts synergistically with eugenol and contributes to the anti-inflammatory and antitumor activities of the plant (Pandey *et al.,* 2023). Sesquiterpenes like β-Caryophyllene and α-Humulene function as dietary cannabinoids which interact with cannabinoid (CB2) receptors, providing its anti-inflammatory, neuroprotective and anti-tumor effects (Liñán-Atero *et al.,* 2024). Phenolic acids and tannins like gallic acid, hydrolysable tannins and other phenolic compounds like ellagic, ferulic, caffeic and salicylic acids express strong astringent, antioxidant, antibacterial and antiviral effect (Faqer *et al*., 2022). *S. aromaticum* has an exceptionally high concentration of flavonoids (quercetin and kaempferol) that possess strong anti-inflammatory, immune-modulating and potential chemoprotective traits (Kabbashi *et al*., 2026)

Recent studies have begun investigating its efficacy, primarily in animal models. These studies reported that key bioactive constituents including eugenol, α-humulene, β-caryophyllene, gallic acid, quercetin, and luteolin demonstrated antioxidant, anti-inflammatory and neuroprotective properties by scavenging free radicals, reducing oxidative stress, modulating calcium channels and reducing neuroinflammation (Sargsyan *et al.,* 2025). The phytochemicals found in *S. aromaticum* also interact synergistically to exhibit broad spectrum, multi-target anti-bacterial and anti-virulence activities against a wide array of pathogens (Tariq *et al.,* 2025).

S. aromaticum has been known to influence the female reproductive system and hormone levels in related animal studies by increasing estrogen and progesterone levels and displaying antioxidant effects (Taghipour *et al.*,2023a, Adeuma and Fente, 2024). In polycystic ovarian syndrome models, *S. aromaticum* has been found to ameliorate imbalances in FSH-LH ratios, decrease testosterone levels and improved ovarian morphology (Taghipour *et al.*,2023a).

Ovarian hormone fluctuations during the rodent estrous cycle significantly influence brain physiology and disease susceptibility, however, despite this profound impact, biomedical research routinely overlooks this physiological variable. Crucially, two major scientific blind spots persist: how external substances alter estrous cycle duration, and how *S. aromaticum* specifically impacts the histology of the ovarian tissue. Virtually no data exists regarding the cellular and structural changes this plant induces within the ovaries. To address these critical knowledge gaps, this study investigates the effects of *S. aromaticum* on rat estrous cycle length, directly comparing its activity against the standard fertility drug CC. Furthermore, it provides a much-needed, detailed analysis of ovarian histology. By pinpointing exactly how *S. aromaticum* modulates cycle timing and microanatomy, this research aims to illuminate the completely unmapped reproductive and biological outcomes of this substance.

MATERIALS AND METHODS

Plant Collection and Authentication: Dried cloves (*S. aromaticum)* were purchased from Gamboru Market in Maiduguri, Borno State. The cloves were authenticated by a Taxonomist from the Faculty of Pharmacy, University of Maiduguri. A voucher specimen of this plant was kept in the Herbarium in the Faculty of Medicine with a specimen voucher number was given for reference (UMM/FPH/MOG/011).

Preparation of Ethanol Extract of Cloves: The ethanolic extract was prepared using the standard Soxhlet (continuous hot) extraction method to ensure high yield and efficiency. This was done to isolate bioactive compounds present in the dried cloves. They were thoroughly cleaned with distilled water to remove dust and impurities. The cloves were then shade-dried to prevent degradation of heat-sensitive phytoconstituents and ground using an electric grinder to obtain a fine powder which was passed through a standard mesh to ensure uniform particle size. Analytical grade ethanol was diluted with water (70% ethanol to 30% water) to ensure efficient extraction of both polar and moderately polar compounds. The

S. aromaticum powder was placed in a thimble of a Soxhlet apparatus using ethanol as the reflux solvent. The solvent was heated to its boiling point and condensed ethanol continually percolated through the plant material for about 7 hours, efficiently recovering the thermotolerant components of *S. aromaticum*. This continued until the solvent in the siphon arm became clear, indicating exhaustive extraction The crude liquid extract was then passed through Whatman filter paper No. 1 to separate the liquid filtrate from the residual solid plant debris. The filtrate was concentrated using a rotary evaporator at a temperature of 40-45°C to recover the ethanol and avoid thermal degradation of bioactive compounds. The concentrated extract was then further dried in a desiccator to remove any residual moisture, resulting in a crude solid extract. The dried extract was then stored in an airtight container at 4°C. For administration, it was freshly reconstituted in an appropriate vehicle to achieve the desired doses. This protocol was carried out according methods described by Abubakar and Haque (2020), de Rosa *et al*., (2024). The Soxhlet extraction of 500 g of powdered cloves with 70% ethanol yielded 108 g of dried extract, corresponding to an extraction yield of 21.6%

Ethical Approval: The protocol for the current experimental study was approved by the Animal Care and Use Committee, Faculty of Veterinary Medicine, through the Ethical Committee of Animal Use, University of Maiduguri. All procedures involving the use of the rats comply with the ethical guidelines for the care and use of animals in research by the National Research Council (NRC) and the ARRIVE Guidelines. The Department of Human Anatomy Ethical Committee, University of Maiduguri gave the approval for the study (UM/HA/UGP25.26-072). Ketamine injection was used as anesthesia to minimize suffering. The current study followed the 3R principle to guide ethical animal use including the use of minimum number of animals required to obtain valid statistically significant scientific results and handling animals to minimize pain, distress or discomfort.

Experimental Animals: The study used 20 adult female Wistar rats (*Rattus norvegicus*) with ages ranging from 10-12 weeks and weighing 150-200g, which were obtained from the National Veterinary Institute, Vom, Plateau State, Nigeria. The animal house had an approximately relative humidity of 50-60% and a 12-hour light/12-hour dark cycle was maintained. They were kept in metal cages in the animal house of the Department of Biochemistry, University of Maiduguri, Borno. The rats were allowed to acclimatize to the standard laboratory conditions for a period of two weeks before the commencement of the experiment. Standard rodent pellet diet and water was provided *ad libitum* during the course of the experimental study.

Experimental Design: This study was conducted as a controlled laboratory-based in vivo experiment over a 21-day period. Twenty rats were randomly assigned to four experimental groups using a computer-generated randomization schedule, with five rats in each group. Group I served as the control group and received an equivalent volume of distilled water. Group II served as the standard drug control and received 50 mg/kg body weight of clomiphene citrate (CC). Groups III and IV received 200 mg/kg and 400 mg/kg body weight of ethanolic extract of *S. aromaticum*, respectively.

The dosage of CC used was as determined from previous studies (Lamfon and Lamfon, 2015). The doses of 200 and 400 mg/kg body weight of *S. aromaticum* extract were selected based on the findings of a preliminary pilot study conducted before the main experiment. The pilot study included an acute toxicity assessment to determine the tolerability of the extract and establish appropriate dose levels for subsequent experimental administration. Based on these preliminary findings, 200 mg/kg and 400 mg/kg were selected as the low and high doses, respectively, for the present study. The vehicle for the extract was distilled water. Oral gavage volume for each rat was calculated based on the animal weight (ml/kg). These were individually calculated prior to administration. All treatments were administered once daily by oral gavage using an orogastric tube for 21 consecutive days. Treatment was initiated after the animals were identified as being in the diestrous phase, following monitoring of the estrous cycle for several days before treatment. Thereafter, the respective treatments were administered once daily throughout the 21-day experimental period, irrespective of the subsequent stage of the estrous cycle. Vaginal smears were collected daily to identify and monitor the successive stages of the estrous cycle, including proestrous, estrous, metestrous, and diestrous (Kilic-Okman *et al.*,2003). The investigators responsible for administering treatments, assessing outcomes, and analyzing the micrographs were blinded to group allocations and treatment for the duration of the experiment to minimize observer and performance bias.

Estrous Cycle Monitoring: The estrous cycle was monitored in the rats by the collection method (vaginal lavage). This method was selected compared to the swabbing method to minimize cell distortion which is common with the swabbing method. The rats were placed on a clean surface, then restrained by lightly gripping the loose skin on the back of the rat's neck. The tail was gently lifted to expose the genital region. A pipette was loaded with 100µL of saline and its tip was slowly inserted into the vagina to a depth of about 5-10 mm. The saline was gently flushed in and out till the fluid appeared cloudy. This fluid was placed on a labelled slide to transfer the cells. The slide labelled with the date, time and animal ID. A clean pipette was used for each rat to prevent cross-contamination. The slides were air-dried, fixed in 75% alcohol, and stained with crystal violet and allowed to dry for 7-10 minutes. A cover slip was applied using DPX and then the slides were observed under a light microscope at a magnification of X10 and X40 to observe the cell morphology and to determine

the stage of the estrous cycle (proestrous, estrous, metestrous and diestrous). This was done according to procedures described by Bedan *et al.,* (2025), Bedan *et al.,* (2026). The duration of each stage was recorded and the cycle regularity was also evaluated. Treatment was initiated during the diestrous phase of the estrous cycle. Diestrous was selected to provide a consistent and identifiable physiological starting point for all animals, as this phase can be readily identified by the predominance of leukocytes in vaginal cytological smears. Initiating treatment at the same stage of the cycle was intended to minimize inter-animal variation in baseline reproductive status and facilitate assessment of treatment-related changes in subsequent estrous cycle phases.

Behavioral Observations Observed During the Estrous Cycle: The rats were noted during the experimental study to observe any change in their behavior during the estrous cycle.

Animal Euthanasia and Organ Procurement: The rats were sacrificed at the end of the treatment period by inducing sleep by administering ketamine hydrochloride (Ralingtonpharma LLP, India). The injection was given to the right thigh of each rat and rats were placed on a sterilized surface where laparoscopic procedure was performed to make a horizontal midline incision performed to expose abdominal and pelvic organs (Attah *et al*., 2022). The ovaries were removed from the abdominal cavity subjected to routine histological processing to observe the effect of the extract on these tissues according to procedures carried out by Mutah *et al.,* (2020), Dani *et al.,* (2022).

Histological Preparation: The procedures were carried out according to procedures described by Ishaya *et al.,* (2018), Malgwi *et al.,* (2025). The ovaries were fixed in Bouin's fluid (Sigma-Aldrich (Merck), Brazil), for approximately 12 hours at room temperature. The fixed ovaries were thoroughly washed in 70% ethanol to remove the yellow picric acid color from the tissue with multiple changes of 70% ethanol over the following 24-48 hours. Dehydration was carried out preparing the ovaries for paraffin infiltration by immersing them in several series of ethanol from 70% to absolute alcohol. The tissue was cleared in Xylene (Veckridge Chemicals, New Jersey) to remove the alcohol and make the ovary tissue receptive to paraffin. It was then infiltrated with paraffin wax by transferring the cleared tissue into molten paraffin wax in an oven at 56-58°C. The infiltrated tissue was embedded in a paraffin block, ensuring that a correct orientation so that the follicles could be sectioned through the cortex. The tissue was then sectioned using a microtome (Leica RM2125 Rotary Microtome), to obtain a 5µm thickness. The embedding process was reversed to dewax the tissue and allow dyes to penetrate the sections by running them through Xylene to clear and alcohol to rehydrate. The tissue was stained with Hematoxylin and Eosin (Abbey Color, Philadelphia). The sections were then photographed using an Amscope light microscope (MBJX- ISCOPE, Los Angeles) with a digital camera (M500, X64, version 3.7) under X40 to observe the general architecture of the ovary and X400 magnification to observe the ovarian follicles closely.

The ovarian histological assessment was qualitative and was used to describe the presence and morphological appearance of different follicular stages and corpora lutea. Care was taken to identify a follicle is only if the oocyte nucleus (or nucleolus) was clearly visible in that specific section of the micrograph. Follicles on a micrograph are categorized not by millimeter size, but by the physical shape and layers of the surrounding granulosa cells. Primordial follicles were recognized as a small oocyte surrounded by a single layer of flattened (squamous) granulosa cells, Primary follicles were recognized as an oocyte surrounded by a single layer of cuboidal granulosa cells, while secondary / preantral follicles were recognized as two or more complete layers of cuboidal granulosa cells, but no visible fluid cavity (antrum).Antral follicle were identified as containing a clearly defined, fluid-filled antral cavity and Graafian follicles were determined by their massive antrum; with the oocyte is pushed entirely to one side, held by a stalk of cells (*cumulus oophorus*). Atretic follicles were excluded where the micrograph showed a fragmenting oocyte, a misshapen border, or a high ratio of dying (pyknotic) granulosa cells relative to dividing /mitotic cells. These criteria were as outlined by Uslu et al., (2017), Hassan et al., (2024).

Statistical Analysis: The individual rat was considered the experimental and statistical unit, with five animals in each experimental group. Vaginal cytological examinations were performed repeatedly throughout the 21-day experimental period; however, repeated observations obtained from the same animal were not considered independent observations. The daily vaginal smear results were used to identify the stage of the estrous cycle and calculate the duration of each phase for each individual animal. Consequently, the duration of proestrous, estrous, metestrous, and diestrous was summarized at the animal level and used for statistical comparisons between experimental groups. Data were expressed as mean ± standard error of mean (SEM). Differences among groups were analyzed using Tukey's post-hoc test, with statistical significance set at $p<0.05$. The data were analyzed using GraphPad Prism 10 (GraphPad software San Diego, USA).

RESULTS

Behavioral Observations Observed During the Estrous Cycle: In the proestrous stage, rats in all groups were observed to be hyperactive and appeared calm, showed increased social behavior. In the estrous stage, the rats exhibited sexual receptibility behavior including exhibiting the mating posture (lordosis) and wiggling of ears. They were also activities recorded including hopping around observed in all groups. In the metestrous stage, rats in all groups did not express mating posture and were restless, when compared to the estrous phase. In the diestrous stage, rats displayed an anxious-like behavior with decreased social and exploratory tendencies compared to the estrous group. There was no difference in the behavior of extract treated groups compared with the control groups.

The Effect of *S. aromaticum* on the Estrous Cycle Cytology: In all groups, the predominant cells found in the proestrous group were rounded and nucleated epithelial cells (Figures 1A-D). In the slide representing Group IV, clumps of nucleated epithelial cells were observed (Figure 1D). The estrous period showed predominant anucleated irregularly shaped cells with fewer nucleated cells seen (Figures 2A-D). The slides representing metestrous had a mix of leucocytes, cornified cells and nucleated cells (Figures 3A-D). In the diestrous stage, there were very few anucleated and nucleated epithelial cells with leucocytes being the predominant cell type (Figures 4A-D).

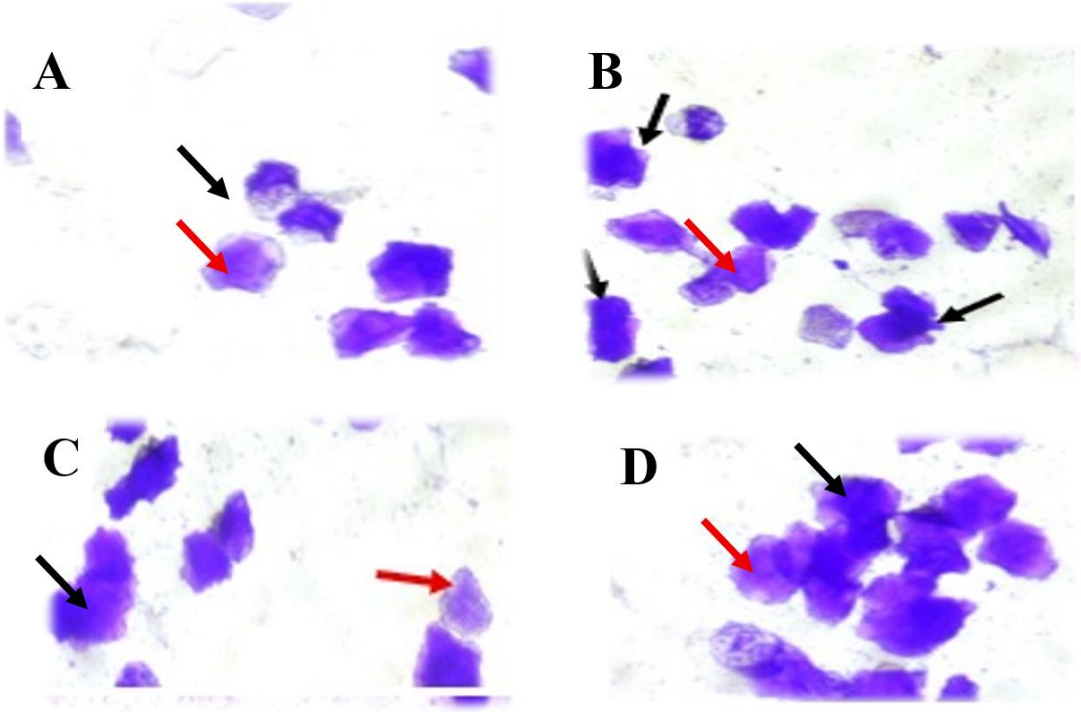

Figure 1 showing the vaginal smear in all groups in the proestrous stage showing nucleated epithelial cells (black arrow) in all groups. Few cornified anucleated cells (red arrow) are also seen. A- Group I, B – Group II, C- Group III, D – Group IV. n=5, Crystal Violet X100



Figure 2 showing the vaginal smear in all groups in the estrous stage showing fewer nucleated epithelial cells (black arrow). The predominant cells observed in this stage are anucleated cornified cells (red arrow). A- Group I, B – Group II, C- Group III, D – Group IV. n=5, Crystal Violet X100

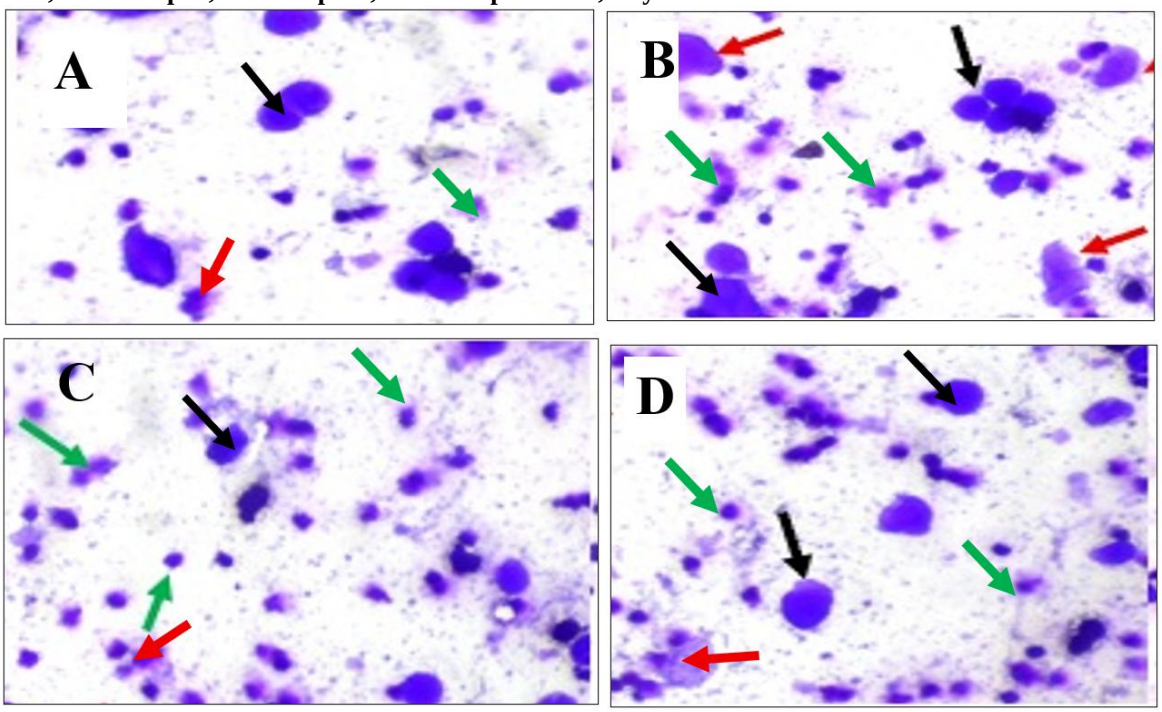

Figure 3 showing the vaginal smear in all groups in the metestrous stage showing nucleated epithelial cells (black arrow), anucleated cornified cells (red arrow) and leucocytes (green arrow). A- Group I, B – Group II, C- Group III, D – Group IV. n=5, Crystal Violet X100

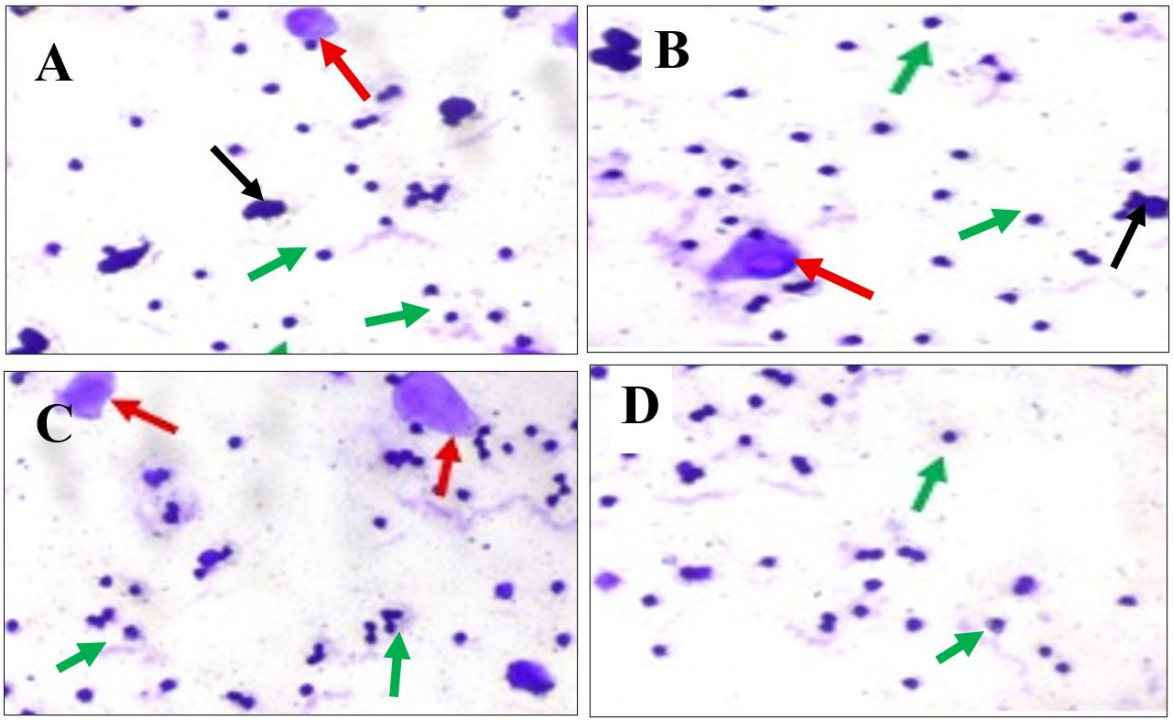

Figure 4 showing the vaginal smear in all groups in the diestrous stage showing predominant leucocytes (green arrow) a few nucleated epithelial cells (black arrow), and anucleated cornified cells (red arrow) and leucocytes A- Group I, B – Group II, C- Group III, D – Group IV. n=5, Crystal Violet X100

The Effect of *S. aromaticum* on the Histology of the Ovary: Figure 5A represents the micrograph of the ovary of control rats showing normal ovary tissue with corpora lutea in the stroma of the ovary identified by the deeply staining Eosinophilic granulosa cells which appear darker stained when compared with the neighboring tissue. Graafian follicles were identified as cells with a mature ovum which was surrounded with granulosa cells and a centrally located fluid-filled cavity. Few secondary follicles were observed in this group. Rats in Group II were treated with CC and revealed ovaries which had smaller corpora lutea. Several Graafian follicles were also seen in the stroma of ovaries in this group. The primary follicles were identified by the single layer of cuboidal granulosa cells and secondary follicles had multiple layers of granulosa cells. The ovarian stroma had numerous blood vessels supplying the structures described (Figure 5B).

Rats in Group III were treated with a low dose of *S. aromaticum* and the micrograph revealed several corpora lutea, primary follicles and secondary follicles. The ovary also had numerous blood vessels (Figure 5C). Figure 5D showed micrographs from the rats that were treated with high dose of *S. aromaticum* and had corpus lutea, primary, secondary and tertiary follicles present. Antral follicles had small areas filled with follicular fluid. Thecal cells were separated from granulosa cells by the basement membrane. Numerous capillaries were seen in the ovarian stroma as seen in Groups II and III.

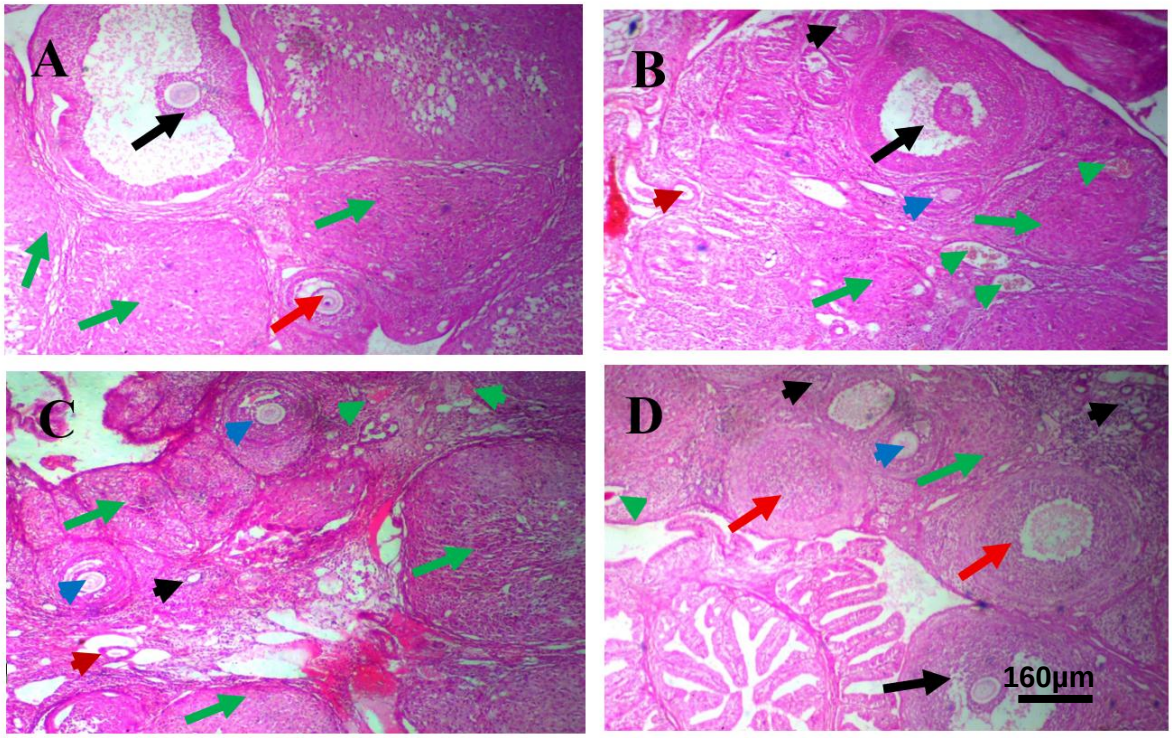

Figure 5 showing the histology of the ovaries in all groups showing Graafian follicle (black arrow), tertiary follicles (red arrow), secondary follicles (blue arrow head) and primary follicles (black arrow head) and corpus luteum (green arrow), blood vessels (green arrow head). A- Group I, B – Group II, C- Group III, D – Group IV. n=5, HandE X 400.

The Effect of *S. aromaticum* on the Duration of the Estrous Cycle

The Effect of *S. aromaticum* on the Proestrous Stage of the Estrous Cycle: Groups I and II had similar, shorter proestrous durations (mean 10.0 h and 9.4 h), and the difference between them was not significant. Groups III and IV had longer proestrous durations (mean 12.0 h and 13.0 h) than both Group I and Group II, with highly significant differences ($p<0.0001$) in all four comparisons. Group III and Group IV also differed significantly from each other ($p<0.05$), with Group IV showing the longest proestrous stage overall. This indicates that while the two lower-duration groups were statistically indistinguishable, the two higher-duration groups were both significantly elevated above them and modestly different from each other. Variability (SD) was low across all groups (0.5–1.3 h), indicating fairly consistent, tightly clustered values within each group (Figure 6, Table 1).

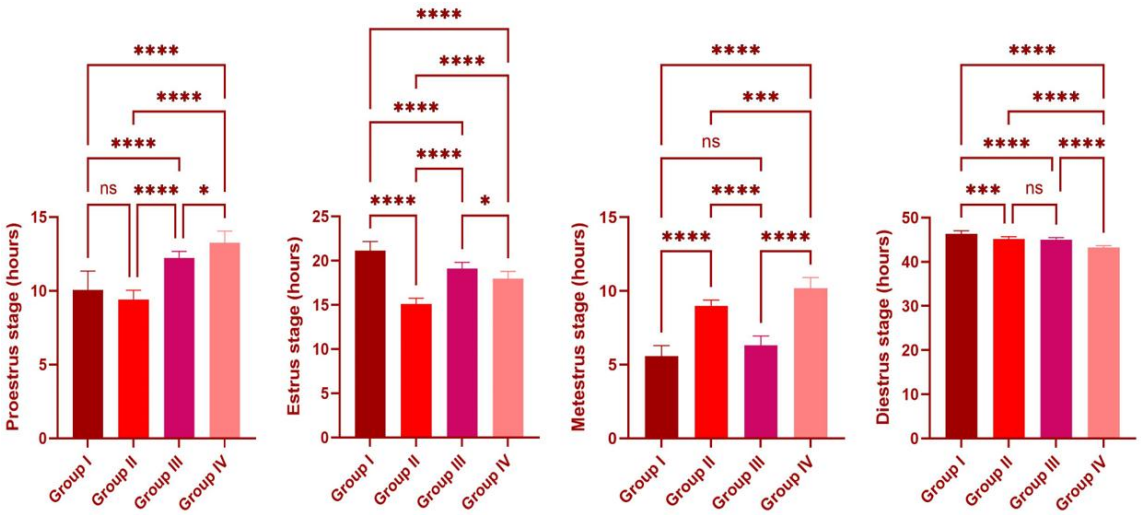

Figure 6 showing the duration of the stages of the estrous cycle in all groups. Ns- not significant, (*p<0.05), (p<0.01), (*** p<0.001), (**** - p<0.0001). Values are represented as mean ± SEM, n=5.**

Table 1: Showing the Descriptive Statistics between the Groups in the Proestrus Stage

Descriptive Statistics	Group I	Group II	Group III	Group IV
Minimum	8.0	8.5	12.0	12.0
Maximum	12.0	11.0	13.0	14.0
Range	4.0	2.0	1.3	2.0
Mean	10.0	9.4	12.0	13.0
Standard Deviation	1.3	0.6	0.5	0.8
Standard Error of Mean	0.4	0.2	0.1	0.3

The Effect of *S. aromaticum* on the Estrous Stage of the Estrous Cycle: The estrous stage showed significant differences across nearly every group comparison. Group I showed the longest estrous duration (mean 21.1 h), significantly higher than all other groups ($p<0.0001$). Group II had the shortest estrous duration (mean 15.1 h), significantly lower than every other group ($p<0.0001$ vs Groups I and III; $p<0.05$ vs Group IV). Groups III and IV had intermediate values (19.1 h and 18.0 h respectively) and differed significantly from each other ($p<0.05$). No comparisons in this stage were non-significant, indicating that estrous duration was statistically distinct across all four groups. Estrous duration decreased from Group I to III to IV to II, which was essentially the reverse order of the proestrous trend (Figure 6, Table 2).

Table 2: Showing the Descriptive Statistics between the Groups in the Estrous Stage

Descriptive Statistics	Group I	Group II	Group III	Group IV
Minimum	19.0	14.0	18.0	17.0
Maximum	22.3	16.0	20.0	19.0
Range	3.3	2.0	2.0	2.0
Mean	21.1	15.1	19.1	18.0
Standard Deviation	1.0	0.6	0.7	0.8
Standard Error of Mean	0.3	0.2	0.2	0.3

The Effect of *S. aromaticum* on the Metestrous Stage of the Estrous Cycle: Group I and Group III had the shortest metestrous durations (5.6 h and 6.3 h) and were not significantly different from each other. Group II and Group IV had noticeably longer metestrous durations (9.0 h and 10.2 h), each significantly higher than Groups I and III ($p<0.0001$). Group II and Group IV also differed significantly from each other, with Group IV showing the longest metestrous phase of all groups. This is the opposite pattern from proestrous and estrous, where Groups I and III tended to run higher rather than lower. In the metestrous stage, Group I and Group III did not differ significantly from one another (ns), suggesting comparable durations between these two groups (Figure 6, Table 3).

Table 3: Showing the Descriptive Statistics between the Groups in the Metestrous Stage

Descriptive Statistics	Group I	Group II	Group III	Group IV
Minimum	4.0	8.0	5.0	9.0
Maximum	6.3	9.5	7.0	11.0
Range	2.3	1.5	2.0	2.0
Mean	5.6	9.0	6.3	10.2
Standard Deviation	0.7	0.3	0.6	0.7
Standard Error of Mean	0.2	0.1	0.2	0.2

The Effect of *S. aromaticum* on the Diestrous Stage of the Estrous Cycle: Group I had the longest diestrous duration (mean 46.3 h), significantly greater than all other groups. Groups II and III were very similar (45.1 h and 45.0 h) and not significantly different from each other, though both differed significantly from Group I and Group IV. Group IV had the shortest diestrous duration (mean 43.2 h), significantly lower than all three other groups ($p<0.0001$). This pattern indicates that Groups II and III behaved similarly to each other in this stage, while Group I and Group IV each stood apart as statistically distinct, at the high and low ends of duration, respectively (Figure 6, Table 4).

Table 4: Showing the Descriptive Statistics between the Groups in the Diestrous Stage

Descriptive Statistics	Group I	Group II	Group III	Group IV
Minimum	45.0	44.0	44.0	43.0
Maximum	47.5	46.0	46.0	44.0
Range	2.5	2.0	2.0	1.0
Mean	46.3	45.1	45.0	43.2
Standard Deviation	0.7	0.6	0.5	0.4
Standard Error of Mean	0.2	0.2	0.1	0.1

DISCUSSION

The estrous cycle is a fundamental biological variable in research, accounting for it is crucial as fluctuations in ovarian hormone levels affect brain physiology, gene expression and disease risks in female mammals (Kapp, 2013). Assessment of the estrous cycle in experimental animals is a useful measure of the integrity of the hypothalamic-pituitary-ovarian axis and the functioning reproductive status of the female reproductive system (Pantier *et al.*,2019). Understanding and incorporation of the estrous cycle in research studies provides mechanistic insight and helps pinpoint whether behavioral or physical outcomes are determined by high estrogen (proestrous), decreasing estrogen (estrous) or high progesterone (diestrous) (Rocks *et al.*,2022). Determining the estrous phase is essential for selecting a female animal that will mate when paired with a male counterpart to achieve timed-pregnancy or tracking of estrous as a variable that may affect research (Ajayi and Akhigbe, 2020).

During the experimental period, qualitative behavioral observations were made in relation to the different stages of the estrous cycle. Rats observed during the proestrous phase generally exhibited increased locomotor activity and social interaction, whereas those in the estrous phase displayed characteristic sexually receptive posture. During the metestrous and diestrous phases, the rats were generally observed to exhibit relatively reduced physical activity and increased anxiety-related behavior. These observations are descriptive and were not based on a predefined behavioral scoring system; therefore, they were not subjected to quantitative statistical analysis. However, the present observations correlated with studies by Pyeon *et al.,* (2023) that attributed the behaviors exhibited in the estrous stage to behaviors linked to rewards and survival. Peak activities were reported to occur in the proestrous and estrous groups and this was attributed to an evolutionary response to mate seeking. Dopaminergic activation by elevated estrogen levels during these phases may activate the brain's reward centers to increase motivated behavior and physical activity (Chen *et al.*,2009). The relatively calm behavior observed in the proestrous and estrous groups was attributed to high levels of estradiol and progesterone in these stages which has a calming effect on female rats, allowing them leave safe areas to find their mates (Pestana and Graham, 2024). In contrast, the anxious behaviors exhibited during the metestrous and diestrous phases could be as a result of a drop in hormone levels which makes the rat cautious and vigilant when not being sexually receptive (Steiner *et al.*,1981). Administration of *S. aromaticum* did not cause behavioral changes in treated rats when compared with the control and CC administered rats.

Monitoring of the estrous cycle in experimental studies are essential in detecting whether substances disrupt the normal, cyclical pattern. Accounting for the cycle stages can reduce errors, improve data consistency, and enhance the

relevance of results to female reproductive health (Ajayi and Akhigbe, 2020). Cytological assessment of vaginal smears is a useful tool for identifying estrous cycle stages in rats. Three main cell types are detected in vaginal smear samples. These are nucleated epithelial cells, cornified squamous epithelial cells, and leukocytes. The ratio of the cell types present in the smear can be used to identify the estrous cycle stages (Ahmed *et al.*,2018). In the current study, *S. aromaticum* did not cause any significant change in the vaginal cytology of the treated rats when compared to the control and CC-treated groups.

In the present investigation, administration of *S. aromaticum* significantly increased the proestrous phase and reduced estrous phase when compared to the control group and also significantly decreased the metestrous and diestrous phases of the cycle also when compared to the control group. This may suggest that *S. aromaticum* could act as powerful regulator of the reproductive cycle by suppressing the estrous phase and mimicking or extending the luteal phase of the cycle. This is significant in controlling breeding time, suppressing heat in competition animals, mitigating behavioral changes that are associated with heat, and studying reproductive disruption caused by stress or environmental toxins (Moss and Lu, 2025).

The mechanism of action may be via the hypothalamo-pituitary-gonadal axis. High progesterone levels (or high levels of substances that mimic it) signals the pituitary gland to suppress the FSH/LH surge required for ovulation. Since ovulation is blocked, estrogen levels do not rise to the threshold required for behavioral heat and the animal has a reduced estrous phase.

In the present investigation, administration of *S. aromaticum* significantly increased the duration of the proestrous phase and reduced the duration of the estrous phase compared with the control group. The extract also significantly reduced the metestrous (low dose group) and diestrous phases compared with the control group. These findings indicate that *S. aromaticum* altered the temporal pattern of the estrous cycle in female rats. However, because circulating reproductive hormones and ovulation were not assessed, the observed changes cannot be attributed specifically to alterations in estrogen, progesterone, FSH, or LH concentrations. Similarly, the changes in cycle duration should not necessarily be interpreted as evidence of improved reproductive function, as altered cyclicity may also reflect endocrine modulation or disruption. Therefore, the effects observed in the present study are best described as modulation of estrous-cycle dynamics rather than enhancement of reproductive function.

The physiological mechanisms underlying these changes remain uncertain. The hypothalamo-pituitary-gonadal (HPG) axis regulates ovarian function and estrous-cycle progression, and disturbances in gonadotropin or ovarian steroid signalling can alter the duration of individual cycle phases. Although modulation of this axis could represent one possible explanation for the present findings, the absence of hormonal measurements prevents confirmation of changes in FSH, LH, estrogen, or progesterone. In particular, the reduction in the estrous, metestrous, and diestrous phases cannot be taken as evidence of progesterone-like activity or suppression of the LH surge. Further endocrine investigations are therefore required to determine whether the observed changes involve alterations in HPG-axis signalling.

The prolonged proestrous phase observed following *S. aromaticum* administration may be associated with alterations in ovarian activity; however, increased estrogen production cannot be confirmed from the present data because estrogen concentrations were not measured. Similarly, the reduction in metestrous and diestrous phases should not be interpreted as evidence of a shortened or extended luteal phase or as a direct consequence of reduced progesterone levels. These interpretations remain hypothetical and require confirmation through measurement of circulating reproductive hormones. In a letrozole-induced polycystic ovarian syndrome (PCOS) model, *S. aromaticum* was reported to improve disruption of estrous cyclicity, restore the estrous phase, and reduce cystic follicles (Taghipour *et al*., 2023a). Although these findings provide relevant comparative evidence, differences in experimental models and study outcomes should be considered when interpreting the present results.

In the current study, ovarian histological examination showed follicles at different stages of development, including secondary, tertiary, and Graafian follicles, in the extract-treated groups. These findings indicate that follicular structures at various developmental stages were present following *S. aromaticum* administration. However, because follicles were not quantitatively counted and histological findings were not subjected to statistical analysis, the present observations cannot establish that the extract enhanced folliculogenesis or increased follicular number. Likewise, the presence of more advanced follicular stages does not provide sufficient evidence to conclude that *S. aromaticum* stimulated granulosa-cell proliferation, theca-cell differentiation, antrum formation, or ovulation. These processes may be involved in follicular development, but they were not directly evaluated in the present study (Zeleznik, 2004). The observation that higher doses of *S. aromaticum* were associated qualitatively with more prominent Graafian and tertiary follicles is consistent with previous observations reported by Taghipour *et al.* (2023a), although quantitative assessment would be required to confirm a dose-related follicular response.

The present findings can be considered alongside reports of reproductive-cycle alterations associated with other medicinal plants. Kainugu *et al.* (2018) demonstrated that *Croton menyharthii* and *Uvariodendron kirkii* altered the overall estrous cycle in rats, including changes in the diestrous and metestrous phases. Similarly, *Ficus asperifolia* was reported

to disrupt the estrous cycle by increasing the frequency of the proestrous and estrous phases (Ngadjui *et al*., 2013). Other plants have also been associated with alterations in individual estrous-cycle phases; *Nelumbo nucifera* significantly extended the diestrous phase (Mutreja *et al*., 2008), while *Anethum graveolens* altered the cycle by prolonging the diestrous stage (Malihezaman *et al.*, 2012). Furthermore, *Piper longum* (Linn) has been documented to cause significant estrous-cycle disruption (Thakur *et al.*, 2009). *Jatropha curcus* seeds were also reported to arrest the estrous cycle at the diestrous phase (Mujumdar *et al.*, 2000). In contrast to the present findings, Kage *et al.* (2009) reported that *Trichosanthes cucumerina* significantly prolonged the estrous and metestrous phases while reducing the diestrous phase. Collectively, these studies demonstrate that medicinal plants can produce diverse effects on estrous-cycle dynamics, and changes in cycle duration alone should not automatically be interpreted as beneficial reproductive effects.

Although hormonal assays were not performed in the present study, previous studies provide possible explanations that warrant further investigation. Adeuema and Fente (2024) reported endocrine-modulating effects of *S. aromaticum*, including changes in estrogen and progesterone levels, and suggested possible interactions with estrogenic receptors or effects on the metabolism and clearance of sex hormones. However, these mechanisms cannot be confirmed in the present study and are therefore considered possible explanations rather than demonstrated mechanisms. Similarly, Adeuma *et al.* (2025) reported that low-to-moderate exposure to *S. aromaticum* preserved the structural integrity of female reproductive organs, whereas higher doses were associated with mild degenerative changes in the uterus and fallopian tubes, reduced uterine mass, and alterations in follicular maturation patterns. These findings suggest that the reproductive effects of *S. aromaticum* may vary according to dose and experimental conditions, but further mechanistic studies are necessary.

In studies related to reproductive malignancies, *S. aromaticum* extract was reported to downregulate inflammatory cytokines and induce apoptosis in abnormal cells through mechanisms associated with its dominant phenolic compounds (Taghipour *et al.*, 2023b). In the male reproductive tract, *S. aromaticum* has been reported to influence steroidogenic enzymes, particularly Δ^5 3β-HSD (hydroxysteroid dehydrogenase) and 17β-HSD, with associated changes in serum testosterone levels and epididymal and seminal vesicle secretory functions (Singh and Mishra, 2013). Conversely, higher doses were reported to suppress these enzymes, resulting in reduced testosterone levels and structural degeneration of seminiferous tubules, with associated depletion of spermatids and disruption of spermatogenesis (Mishra and Singh, 2008). In injury-model studies, *S. aromaticum* has also been reported to exhibit antioxidant effects by reducing malondialdehyde levels and restoring superoxide dismutase and glutathione peroxidase activities in testicular tissues (Halimi *et al*., 2020). While these findings provide evidence that *S. aromaticum* can influence reproductive and oxidative processes in other experimental settings, they should not be taken as direct evidence of the mechanism responsible for the ovarian and estrous-cycle changes observed in the present study.

Overall, the present findings demonstrate that *S. aromaticum* extract altered estrous-cycle dynamics and was associated with qualitative changes in ovarian histomorphology. The biological basis of these effects remains uncertain because reproductive hormone concentrations, gonadotropin levels, receptor activity, ovulation, and fertility outcomes were not assessed. Therefore, the observed changes should not be interpreted as evidence of enhanced folliculogenesis, multiple ovulations, improved fertility, or superiority to clomiphene citrate. Future studies incorporating quantitative follicular assessment, hormonal profiling, molecular or receptor-level investigations, confirmation of ovulation, and fertility outcomes are necessary to clarify the reproductive effects and underlying mechanisms of *S. aromaticum*.

Clomiphene citrate (CC) was employed in this study as an ovulation-inducing agent that acts by blocking estrogen receptors in the hypothalamus, thereby creating a perceived state of low estrogen levels. This stimulates the pituitary gland to increase the secretion of FSH and luteinizing hormone (LH), which in turn promote the development and release of mature ovarian follicles. Compared to *S. aromaticum*, CC decreased proestrous and estrous phases of the estrous cycle and significantly increased the metestrous and diestrous stages of the estrous cycle. Administration of CC increased the number of primary follicles, although, antral follicles were not as numerous as observed in the extract-treated groups. Similar to the results obtained in the current investigation, high doses of CC have been shown to increase the number of follicles, but reduce the number of mature follicles, suggesting that it stimulates early folliculogenesis but inhibits final maturation stages (Shalev *et al.*,1989). In related studies, CC has been found to reduce the number of ovulated follicles and corpora lutea, acting as an ovulation inhibitor in specific experimental models (Chaube *et al.*,2006). Other studies show that it can inhibit granulosa mitosis in follicles smaller than 200 m and between 401–600 m. It has also been shown to stimulate granulosa cell death, reduce estradiol levels, and increase reactive oxygen species (ROS) in the ovaries of rats, which can reduce oocyte quality. The impact is however highly dependent on dosage and timing (Chaube *et al.*,2014).

Conclusion: The findings of this study demonstrated that *S. aromaticum* extract significantly influenced the stages of the estrous cycle and ovarian histomorphology in female Wistar rats. The extract prolonged the proestrous phase and reduced the estrous and diestrous phases of the cycle, indicating modulation of hormonal activity, likely through estrogenic mechanisms. Qualitative histological analysis further revealed follicular development, with appearance of several mature

follicles, suggesting reproductive potential. In clomiphene citrate treated rats, early follicular development was predominant, with limited number of matured follicles observed. These findings suggest the potential of *S. aromaticum* as a natural agent for altering reproductive cycles. However, the absence of hormonal assays and evaluation of other reproductive organs limits the ability to fully elucidate the underlying mechanisms. Further studies incorporating endocrine profiling and broader reproductive assessments are recommended to validate these findings and explore clinical applications.

Limitations of the study: The present study evaluated the effect of *S. aromaticum* on the duration of the oestrous cycle and the histomorphology of the ovaries, in comparison with rats treated with clomiphene citrate. However, hormonal and oxidative stress biomarker assays were not performed, and histological assessment of other female reproductive organs was not conducted. Quantitative analysis of the ovary was not carried out, Actual fertility outcomes such as mating outcomes were not evaluated. Another limitation of the study is the absence of a formal power calculation to determine number of animals per group. Future studies also should employ a validated behavioral scoring scale to allow objective and reproducible assessment. In addition, phytochemical characterization, extraction yield, eugenol content, and batch standardization of the extract should be evaluated. Further studies should utilize more than one dosage of CC to ensure multiple comparator doses.

Competing interests: The Authors do not have any conflicts of interest to declare

Funding: The current study did not receive any financial assistance/funding/grants.

Data declaration: Data is available upon request from authors

Author' contributions: MOOA, HIB, DJA, and NID contributed to the study concept, statistical analysis, interpretation of results and design. MOOA, HIB, DJA and NID were involved in the material preparation, Data collection was done by DJA and NID. The first draft of the manuscript was written by MOOA, HIB, and NID. assisted in manuscript writing, helped to improve the manuscript, submission and provided feedback during the peer review process. The research was supervised by MOOA, HIB and NID. All authors commented on the final version of the manuscript; all authors read and approved the final manuscript.

Acknowledgement: The authors express gratitude to the staff of the Faculty Basic Medical Sciences, Histology Laboratory and all individuals that participated in and contributed to the project.

REFERENCES

Abubakar, A., and Haque, M. (2020). Preparation of medicinal plants: basic extraction and fractionation procedures for experimental purposes. J. Pharm. Bioallied. Sci, 12(1): 1–10. https://doi.org/10.4103/jpbs.jpbs_175_19

Aduema, W., Erighanyoyefa, F. A., and Deghinmotei, A.-U. (2025). Evaluation of associated changes on the uterus and fallopian tube histology in response to graded doses of *Syzygium aromaticum* (clove) in Wistar Rats. Trop. J. Pharm. Res. *2*(3): 64–69. https://doi.org/https://doi.org/10.26538/tjdr/v2i3.1

Aduema, W., and Fente, A. E. (2024). Effects of *Syzygium aromaticum* (cloves) extract on some reproductive hormones and oxidative stress markers in female Wistar rats. GJBHS. 7(1): 73–79. https://doi.org/10.15580/gjbhs.2024.1.111924170

Ahmed, H., Ali, F., Ahmed, A. E., Ahmed, A. I., and Abdelhameed, E. (2018). Excitatory and inhibitory influence of exogenous neurotransmitters on reproduction in female rats. J. Exp. Appl. Anim. Sci. 2(3): 286–298. https://doi.org/10.20454/jeaas.2018.1469

Ajayi, A. F., and Akhigbe, R. E. (2020). Staging of the estrous cycle and induction of estrous in experimental rodents: an update. Fertil. Res. Pract. 6(5): 1-15. https://doi.org/10.1186/s40738-020-00074-3

Alvord, V. M., and Pendergast, J. S. (2024). The estrous cycle coordinates the circadian rhythm of eating behavior in mice. J. Biol. Rhythms. 39(5): 413–422. https://doi.org/10.1177/07487304241262356

Attah, M. O. O., Watson, J. T., Garba, S. H., and Ufeli, B. S. (2022). *Leptadenia hastata* leaf extract ameliorates oxidative stress and serum biochemical parameters in streptozotocin-induced diabetes in Wistar rats., J. Diabetes Metab. Disord. 21(2): 1273–1281. https://doi.org/10.1007/s40200-022-01017-z

Bedan, H. I., Garba, S. H., Jacks, T. W., Attah, M. O. O., and Dibal, N. I. (2025). Aqueous extract of *Phoenix dactylifera* pollen powder elevates serum levels of sex hormones and enhances fertility in female albino rats: a biochemical and histological study. Eur. J. Anat. 29(3): 363–374. https://doi.org/10.52083/adri5946

Bedan, H. I., Garba, S. H., Jacks, T. W., Attah, M. O. O., and Dibal, N. I. (2026). The influence of date palm pollen (DPP) diet supplementation on various reproductive parameters in female albino Rats. Vet. Arh. 96(3): 309–323.

https://doi.org/10.24099/vet.arhiv.2989

Belozertseva, I. V., Merkulovs, D. D., Kaiser, H., Rozhdestvensky, T. S., and Skryabin, B. V. (2024). Advancing 3Rs: the mouse estrous detector (MED) as a low-stress, painless, and efficient tool for estrous determination in Mice. Int. J. Mol. Sci. 25(17): 9429–9429. https://doi.org/10.3390/ijms25179429

Caligioni, C. S. (2023). Assessing reproductive status/stages in Mice. Curr. Protoc. Neurosci. 48(1). https://doi.org/10.1002/0471142301.nsa04is48

Chaube, S. K., Prasad, P. V., Tripathi, V., and Shrivastav, T. G. (2006). Clomiphene citrate inhibits gonadotropin-induced ovulation by reducing cyclic adenosine 3′,5′-cyclic monophosphate and prostaglandin E2 levels in Rat ovary. Fertil. Steril. 86(4): 1106–1111. https://doi.org/10.1016/j.fertnstert.2006.03.027

Chaube, S. K., Shrivastav, T. G., Prasad, S., Tiwari, M., Tripathi, A., Pandey, A. N., and Premkumar, K. V. (2014). Clomiphene citrate induces ROS-mediated apoptosis in mammalian oocytes. Open J. Apoptosis. 03(03): 52–58. https://doi.org/10.4236/ojapo.2014.33006

Chen, W., Shields, J., Huang, W., and King, J. A. (2009). Female fear: Influence of estrous cycle on behavioral response and neuronal activation. Behav. Brain Res. 201(1): 8–13. https://doi.org/10.1016/j.bbr.2009.01.019

Cora, M. C., Kooistra, L., and Travlos, G. (2015). Vaginal cytology of the laboratory Rat and Mouse. Toxicol. Pathol. 43(6): 776–793. https://doi.org/10.1177/0192623315570339

Dani, S. C., Attah, M. O. O., and Dibal, N. I. (2022). The effect of *Khaya senegalensis* on the endometrial and vaginal epithelium: a histological and morphometrical study. Int. J. Ayurvedic Med. 13(2): 406–411. https://doi.org/10.47552/ijam.v13i2.2621

da Rosa, A., Hoscheid, J., Garcia, V., de Oliveira Santos Junior, O., and da Silva, C. (2024). Phytochemical extract from *Syzygium cumini* leaf: maximization of compound extraction, chemical characterization, antidiabetic and antibacterial activity, and cell viability. Processes. 12(10): 2270. https://doi.org/10.3390/pr12102270

Faqer, O. El, Bendiar, S., Rais, S., Elkoraichi, I., Dakir, M., Elouaddari, A., Amrani, A. El, Oudghiri, M., and Mtairag, E. M. (2022). Phytochemical characterization and immunomodulatory effects of aqueous, ethanolic extracts and essential oil of *Syzygium aromaticum* L. on human neutrophils. Sci Afr. 18:e01395. https://doi.org/10.1016/j.sciaf.2022.e01395

Goldman, J. M., Murr, A. S., and Cooper, R. L. (2007). The rodent estrous cycle: characterization of vaginal cytology and its utility in toxicological studies. Birth Defects Res. B Dev. Reprod. Toxicol. 80(2): 84–97. https://doi.org/10.1002/bdrb.20106

Halimi, M., Pourlak, T., Kalarestaghi, H., Barghi, B., Moghimian, M., Niazkar, H. R., and Shokoohi, M. (2020). Effects of *Syzygium aromaticum* (clove) extract on male fertility factors and oxidative stress after torsion/ detorsion in adult male rats using intrauterine insemination method. Int. J. Women's Health Reprod. Sci. 10(3): 135–140. https://doi.org/10.15296/ijwhr.2022.24

Hassan, M. H., Reiter, E., and Razzaq, M. (2024). Automatic ovarian follicle detection using object detection models. Sci. Rep. 14(1): 31856. https://doi.org/10.1038/s41598-024-82904-8

Ishaya, H., Omaga, I., Dibal, N., and Attah, M. O. O. (2018). Comparative histomorphology of the ovary and the oviduct in Rabbits and Pigeons. J. Morphol Sci. 35(04): 242–245. https://doi.org/10.1055/s-0038-1675226

Kabbashi, A. S., Shuaib, M. J. A., Shailabi, T. I., Zahran, D. R., Abdulwahed, T. F., Bosharah, H. H., Mohammed, M. F., Saleh, B. M., Elshikh, A. A., Elhag, O. O., Mustafa, A. A., Ghosh, S., Dehghani, M. H., and Ammar, E. E. (2026). Integrated bioactivity assessment of *Syzygium aromaticum* bud extract from Sudan shows antimicrobial and antioxidant potential. Sci. Rep. 6(1): 15562. https://doi.org/10.1038/s41598-026-44797-7

Kage, D. N., Malashetty, V. B., Seetharam, Y. N., Suresh, P., and Patil, S. B. (2009). Effect of ethanol extract of whole plant of *Trichosanthes cucumerina var. Cucumerina* L. on gonadotropins, ovarian follicular kinetics and estrous cycle for screening of antifertility activity in albino Rats. Int. J. Morphol. 27(1): 173-182. https://doi.org/10.4067/s0717-95022009000100030

Kaingu, C., Oduma, J., Mbaria, J., and Kiama, S. (2018). Antifertility and anti-implantation potential of *Croton menyharthii* and *Uvariodendron kirkii* aqueous extract in female Wistar rats. IJMPAM. 112(2018): 844–885.

Kapp, R. W. (2013). Book Review: A comprehensive guide to toxicology in preclinical drug development. Int J Toxicol. 32(6): 464–465. https://doi.org/10.1177/1091581813511227

Kessel, B., and Hsueh, A. J. W. (1987). Clomiphene citrate augments follicle-stimulating hormone-induced luteinizing hormone receptor content in cultured Rat granulosa cells. Fertil. Steril. 47(2): 334–340. https://doi.org/10.1016/s0015-0282(16)50015-6

Kilic-Okman, T., Kucuk, M., and Altaner, S. (2003). Comparison of the effects of letrozole and clomiphene citrate on ovarian follicles, endometrium, and hormone levels in the rat. Fertil. Steril. 80(6): 1330–1332.

https://doi.org/10.1016/j.fertnstert.2003.05.002
Lamfon, H. A., and Lamfon, N. A. (2015). Clomiphene citrate induced kidney injury in female albino Rat. J. Biosci. Appl. Res. 1(2): 39–43.
Liñán-Atero, R., Aghababaei, F., García, S. R., Hasiri, Z., Ziogkas, D., Moreno, A., and Milad Hadidi. (2024). Clove essential oil: chemical profile, biological activities, encapsulation strategies, and food applications. *Antioxidants*. 13(4): 488–488. https://doi.org/10.3390/antiox13040488
Malgwi, H. D., Jonah, R., Attah, M. O. O., and Dibal, N. I. (2025). The Effect of *Azadirachta Indica* A Juss (neem) extract on some female reproductive organs in albino Wistar Rats: a histologic and morphometric study. J. Morphol. Sci. 2024(42): 26–33. https://doi.org/https://doi.org/10.51929/jms.42.26.2025
Malihezaman, M., Mojaba, M., Elham, H., Farnaz, G., and Ramin, M. (2012). Anti-fertility effects of different fractions of *Anethum graveolens L*. extracts on female Rats. Afr. J. Tradit. Complement. Altern. Med. 9(3):336–341 https://doi.org/10.4314/ajtcam.v9i3.6
Mbi Feh, M. K., and Wadhwa, R. (2020). Clomiphene. https://www.ncbi.nlm.nih.gov/books/NBK559292/
Mishra, R. K., and Singh, S. K. (2008). Safety assessment of *Syzygium aromaticum* flower bud (clove) extract with respect to testicular function in Mice. Food Chem. Toxicol. 46(10): 3333–3338. https://doi.org/10.1016/j.fct.2008.08.006
Moss, C., and Lu, K. (2025). Hormonal manipulation of the estrous cycle in mares. Clinical Theriogenology. 17: 49–63. https://doi.org/10.58292/ct.v17.11651
Mujumdar, A. M., Upadhye, A. S., and Misar, A. V. (2000). Studies on antidiarrhoeal activity of *Jatropha curcus* root extract in albino mice. J. Ethnopharmacol. 70(2): 183–187. https://doi.org/10.1016/s0378-8741(99)00167-1
Mutah, N., Bedan, H., Attah, M. O. O., and Dibal, N. (2020). Comparative histomorphological and morphometric analysis of the testes in Agama Lizard and albino Wistar Rat. J. Med. Histol. 4(2): 205–213. https://doi.org/10.21608/jmh.2021.53161.1086
Mutreja, A., Agarwal, M., Kushwaha, S., and Chauhan, A. (2008). Effect of *Nelumbo nucifera* seeds on the reproductive organs of female Rats. Int. J. Reprod. BioMed. 6(1): 7–11.
Ngadjui, E., Watcho, P., Nguelefack, T. B., and Kamanyi, A. (2013). Effects of *Ficus asperifolia* on normal rat estrous cyclicity. Asian Pac. J. Trop. Biomed. 3(1): 53–57. https://doi.org/10.1016/s2221-1691(13)60023-4
Pandey, V. K., Srivastava, S., Ashish, Dash, K. K., Singh, R., Dar, A. H., Singh, T., Farooqui, A., Shaikh, A. V., and Béla Kovács. (2024). Bioactive properties of clove (*Syzygium aromaticum*) essential oil nanoemulsion: a comprehensive review. Heliyon. 10(1): e22437–e22437. https://doi.org/10.1016/j.heliyon.2023.e22437
Pantier, L., Li, J., and Christian, C. (2019). Estrous cycle monitoring in Mice with rapid data visualization and analysis. Bio-Protocol. 9(17): e3354. https://doi.org/10.21769/bioprotoc.3354
Pestana, J. E., and Graham, B. M. (2024). The impact of estrous cycle on anxiety-like behaviour during unlearned fear tests in female rats and mice: a systematic review and meta-analysis. Neurosci. Biobehav. Rev. 164: 105789–105789. https://doi.org/10.1016/j.neubiorev.2024.105789
Pyeon, G. H., Lee, J., Jo, Y. S., and Choi, J.-S. (2023). Conditioned flight response in female rats to naturalistic threat is estrous-cycle dependent. Sci. Rep. 13(1): 20988. https://doi.org/10.1038/s41598-023-47591-x
Quignon, C. (2023). Collection and analysis of vaginal smears to assess reproductive stage in Mice. Curr. Protoc. 3(9): e887. https://doi.org/10.1002/cpz1.887
Rocks, D., Cham, H., and Kundakovic, M. (2022). Why the estrous cycle matters for neuroscience. Biol. Sex Differ. 13(1): 1-14. https://doi.org/10.1186/s13293-022-00466-8
Sanabria, V., Bittencourt, S., de la Rosa, T., Livramento, J., Tengan, C., Scorza, C. A., Cavalheiro, E., and Amado, D. (2019). Characterization of the estrous cycle in the Amazon spiny Rat (*Proechimys guyannensis*). Heliyon. 5(12): e03007. https://doi.org/10.1016/j.heliyon.2019.e03007
Sargsyan, T., Simonyan, H. M., Stepanyan, L., Tsaturyan, A., Vicidomini, C., Pastore, R., Guerra, G., and Roviello, G. N. (2025). Neuroprotective properties of clove (*Syzygium aromaticum*): state of the art and future pharmaceutical applications for Alzheimer's disease. Biomolecules. 15(3): 452–452. https://doi.org/10.3390/biom15030452
Shalev, J., Goldenberg, M., Kukia, E., Lewinthal, D., Tepper, R., Mashiach, S., and Blankstein, J. (1989). Comparison of five clomiphene citrate dosage regimens: follicular recruitment and distribution in the human ovary. Fertil. Steril. 52(4): 560–563. https://doi.org/10.1016/s0015-0282(16)60963-9
Singh, S., and Mishra, R. (2013). Reproductive effects of lipid soluble components of *Syzygium aromaticum* flower bud in male Mice. J. Ayurveda Integr. Med. 4(2), 94. https://doi.org/10.4103/0975-9476.113870
Steiner, M., Katz, R. J., Baldrighi, G., and Carroll, B. J. (1981). Motivated behavior and the estrous cycle in rats. Psychoneuroendocrinology. 6(1): 81–90. https://doi.org/10.1016/0306-4530(81)90051-2

Taghipour, Z., Bahmanzadeh, M., Kahnavi, M., and Sadati, N. (2023). Effects of *Syzygium aromaticum* (L.) Merr. and L.M.Perry aqueous extract on the letrozole-induced model of polycystic ovarian syndrome. J Biol Regul. Homeost. Agents. 37(9): 4749–4759. https://doi.org/10.23812/j.biol.regul.homeost.agents.20233709.463

Taghipour, Z., Bahmanzadeh, M., and Rahimi, R. (2023). The effects of clove and its constituents on reproductive system: a comprehensive review. Reprod Sci. 30(9): 2591–2614 https://doi.org/10.1007/s43032-023-01223-x

Thakur, S., Bawara, B., Dubey, A., Nandini, D., Chauhan, N. S., and Saraf, D. K. (2009). Effect of *Carum carvi* and *Curcuma longa* on hormonal and reproductive parameter of female Rats. Int. J. Phytomed. 1(1): 31–38. https://doi.org/10.5138/ijpm.2009.0975.0185.05791

Tariq, H., Alhudhaibi, A. M., and Abdallah, E. M. (2025). *Syzygium aromaticum* (clove buds) as a natural antibacterial agent: a promising alternative to combat multidrug-resistant bacteria. Front. Microbiol, 16(674590). https://doi.org/10.3389/fmicb.2025.1674590

Uslu, B., Dioguardi, C. C., Haynes, M., Miao, De Q., Kurus, M., Hoffman, G., and Johnson, J. (2017). Quantifying growing versus non-growing ovarian follicles in the Mouse. J. Ovarian Res. 10(1): 3. https://doi.org/10.1186/s13048-016-0296-x

Wolcott, N. S., Sit, K. K., Raimondi, G., Hodges, T., Shansky, R. M., Galea, L. A. M., Ostroff, L. E., and Goard, M. J. (2022). Automated classification of estrous stage in rodents using deep learning. Sci Rep. 12(1): 17685. https://doi.org/10.1038/s41598-022-22392-w

Yilmaz, S., Yilmaz Sezer, N., Gönenç, İ. M., İlhan, S. E., and Yilmaz, E. (2017). Safety of clomiphene citrate: a literature review. Cytotechnology. 70(2): 489–495. https://doi.org/10.1007/s10616-017-0169-1

Zeleznik, A. J. (2004). The physiology of follicle selection. Reprod. Biol. Endocrinol. 2(1): 31. https://doi.org/10.1186/1477-7827-2-31