

## COMPARATIVE EVALUATION OF CONVENTIONAL METHOD AND STAPLED SUTURE TECHNIQUE FOR INTESTINAL ANASTOMOSIS IN DOGS

H. K. Shahzad<sup>1</sup>, M. A. Khan<sup>1\*</sup>, S. G. Bokhari<sup>1</sup>, A. Z. Durrani<sup>1</sup>, M. Asif<sup>1</sup>, I. U. Khan<sup>1</sup>, R. Akhtar<sup>2</sup>, S. Masood<sup>3</sup>, M. A. Khan<sup>1</sup>, F. Ijaz<sup>1</sup>, H. Anjum<sup>1</sup>, M. K. Maan<sup>1</sup>, A. Noor<sup>1</sup>, A. Ullah<sup>1</sup>, M. A. Hayat<sup>1</sup>, M. A. Ali<sup>4</sup> and M. Bilal<sup>1</sup>

<sup>1</sup>Department of Clinical Medicine and Surgery; <sup>2</sup>Department of Pathology, <sup>3</sup>Department of Anatomy and Histology, <sup>4</sup>Department of Microbiology, University of Veterinary and Animal Sciences, Lahore, 54000, Punjab, Pakistan;  
\*Corresponding Author Email address: marif@uvas.edu.pk

### ABSTRACT

This experimental study was conducted to compare the two different techniques of end-to-end anastomosis, hand-sewn vs stapled anastomosis, in the jejunum of dogs. After approval from the Animal Ethical Committee, the research study was tested on 12 healthy mongrel dogs, randomly divided into two different groups (A and B) comprising 6 dogs each. Conventional hand-sewn method of end-to-end anastomosis was applied on group A and stapled anastomosis was performed on the dogs of group-B, using the end-to-end anastomosis (EEA) circular stapling device. Based on physical observations and contrast radiographic findings, there was neither any leakage from the site of anastomosis nor any severe post operative complications in terms of peritonitis, septicaemia or shock. Upon exploratory laparotomy, no significant change was observed in the internal and external diameters at the site of anastomosis, between Groups A and B. However, the suturing time significantly decreased through application of stapled suturing technique (mean:  $44.3 \pm 1.28^{**}$ ;  $P < 0.0002$ ), as compared with the conventional suturing method (mean:  $54.3 \pm 1.23$ ). Based on the physiological parameters and radiographic evaluation, it was concluded that the method of stapled suturing is safe and convenient for use in dogs; the additional advantage of the ease in application makes suturing more rapid, decreases suturing time required, and minimizes chances of post-operative complications.

**Key words:** Stapled sutures; EEA stapler; hand-sewn technique; end-to-end anastomosis; dogs.

### INTRODUCTION

End to end intestinal anastomosis is a surgical procedure which is often indicated for the intestinal resection due to malignant tumors, strictures, ischemic lesions, necrosis, etc. (Vella and O'Dwyer, 2002).

Currently two methods are being used for the purpose of anastomosis; the first one is a hand sewn method, while the second one involves the use of circular surgical stapling device, known as the EEA stapler. Furthermore, the anastomosis can be performed in a single layer or double layers using appositional suturing patterns (simple interrupted, simple continuous), as reported by Nasir Khan *et al.* (2006) and Mitchell *et al.*, (2011). Among the hand-sewn methods of anastomosis, the single layer simple interrupted suturing pattern using absorbable monofilament suture material was considered as the best pattern for end to end intestinal anastomosis and other gastrointestinal surgeries (Coolman *et al.*, 2000). However, with the advent of stapling devices, the ease, convenience in usage and minimal post-operative complications reported in small animals, conventional hand-sewn methods have largely been replaced by staplers (Kavic SM, 2014). Furthermore, it is important to recall that surgical staplers have become an essential part of various gastrointestinal surgeries (Martel and Boushey, 2007).

The various types of staplers which are being used for the purpose of anastomosis include circular ligators, clip applicators, endoscopic staplers etc. The circular stapler is a disposable anastomotic instrument, available with a variety of staple line diameters, which places a round, double staggered row of titanium staples, capable of generating end-to-end, end-to-side, or side-to-side anastomosis (Offodile *et al.*, 2010). The surgical staplers are preferred because of their convenient use and rapid application (Lustosa *et al.*, 2001). They favor the blood flow across the anastomosis; provoke less injury, necrosis and edema (El-Bakry, 2002).

Since the past decade, gastrointestinal surgery in human beings has taken an immense shift from traditional hand-sewn methods towards the use of intestinal staplers; similar increasing trends are reported in small animal gastrointestinal surgeries, since surgical staplers present a possible reduction in operational timing and are easy to learn and use than for hand-sewn methods. These features, coupled with their safety of application makes them a popular choice now-a-days (Lustosa *et al.*, 2001).

Keeping in view the popularity and increasing demand of surgical staplers for intestinal anastomosis, this present study was conducted to compare the conventional hand-sewn method of anastomosis vs the stapled suturing technique in terms of efficacy and safety, in order to sort out the best method for intestinal anastomosis.

## MATERIALS AND METHODS

**Animal preparation and anaesthesia:** After approval by the Animal Ethical Committee at University of Veterinary & Animal Sciences (UVAS), Lahore, 12 healthy mongrel dogs were selected and randomly divided into two groups (A and B) comprising 6 dogs each. They were acclimatized, dewormed, vaccinated, and lodged at the Pet Centre, UVAS, Lahore. Atropine sulphate @ 0.04 mg/ kg (Atrostar<sup>®</sup>, Star Laboratories, Pakistan) and Xylazine HCl @ 1.0 mg/kg (Xylaz<sup>®</sup>, Farvet, Holland), were administered intramuscularly as pre-anaesthetic and sedative, respectively. Thereafter, Ketamine HCl @ 10mg/kg body weight (Ketasol<sup>®</sup>, Indus Pharma Pakistan) was injected intravenously for induction and maintenance.

**Experimental surgeries:** After anaesthetization, the animals were restrained in dorsal recumbency. The intestine (jejunum) was exteriorized through a cranial midline laparotomy. Two non-crushing intestinal clamps were applied over the intestine, 2 cm apart. The intestinal segment was incised on both the sides, along the clamps with the help of scalpel, and then excised. The cut intestinal segments were sutured according to the following methods:

**Group A:** Conventional hand-sewn method of end-to-end anastomosis was applied. Intestinal anastomosis was achieved using a single layer of simple interrupted suturing pattern with an absorbable braided suturing material (Catgut-3/0), (Coolman *et al.*, 2000).

**Group B:** The circular mechanical stapler (EEA<sup>™</sup> 21 mm and 25 mm Single-Use Stapler, (Ethicon<sup>®</sup>, Johnson & Johnson, Pakistan) of 21 and 25 mm in diameter was used to generate end-to-end intestinal anastomosis (Martel and Boushey, 2007). The stapler was introduced through an enterotomy incision made 10 cm away from the proposed site of anastomosis. The stapler was opened and both parts of intestine were secured on the spindle of the stapling instrument. The stapler was closed to achieve proper tissue compression, and then fired by compressing both handles strongly. Finally, the stapling device was opened and removed through the enterotomy incision. After examination of the stapled anastomosis, the enterotomy incision was closed using Catgut 3/0 (Ethicon<sup>®</sup>, Johnson & Johnson, Pakistan) applied as a single layer of simple-interrupted suturing pattern.

### 1. Animal evaluation

**a) Physical parameters:** Post-operatively, the animals were checked three times daily for the clinical parameters of temperature, pulse, respiration, vomiting, diarrhea, blood in feces, gross appearance and peritonitis.

**b) Radiographic evaluation:** Post-surgically, contrast radiography was performed using 56% solution

of barium sulphate @ 12 ml/kg body weight to check any leakage or stenosis formation at the anastomotic site. The radiographs were obtained in ventrodorsal view (Cakabay *et al.*, 2011).

**c) Post surgical observation:** At the end of the experimental period (i.e. 4 weeks), an exploratory laparotomy was performed to measure the intra-luminal diameter of the anastomosed area of the jejunum, inspection of the gross appearance and for detection of any other abnormality if present. An assessment towards stricture formation post-operatively, was also considered. An enterotomy was performed at the anastomosed site and the internal circumference was measured with the help of string which was compared with a scale to take the measurements in centimeter (cm) and then the diameter was calculated.

**d) Suturing time:** The total suturing time was calculated as the time taken from the insertion of the first suture in the intestine till the placement of the last suture.

**e) Statistical analysis:** Paired t-test was applied to evaluate changes in the luminal diameter at the anastomotic site; furthermore, assessment of significance in suturing time between groups A and B was done using a simple t-test. The differences were considered significant at P 0.05.

## RESULTS

**Physical findings:** The temperature of all the dogs was slightly increased, with increased pulse rate, for the first two days, post-operatively; then afterwards, the temperature returned to normal on the third to fourth post-operative day, except for dogs A3 and B1, which suffered from pyrexia and were treated using Diclofenac Sodium (Injection Dicloran<sup>®</sup>, J.B. Chemicals & Pharmaceuticals Ltd., Pakistan) till complete recovery. Death due to possible leakage and subsequent peritonitis was only reported in one dog, Dog A6, from the hand-sewn anastomosis Group A, which suffered consistently high fever (105°C) three days after the surgery; despite aggressive treatment the dog could not survive and the condition proved fatal. Leakage and peritonitis were confirmed at post-mortem.

Respiration rate of dogs, A3 and B1, was found increased on third and fourth post-operative days, respectively, however, it returned to normal after appropriate treatment.

Dogs B4 and A1, vomited on the same day of surgery post-operatively, while dog A3 manifested vomiting after feeding on the sixth day, post-operatively. Vomiting in dogs was controlled through use of Injection Metomid<sup>®</sup> (CCL Pharmaceuticals Pakistan Ltd.), till complete recovery.

Besides this, dogs A5 and B6 passed bloody stool on the very next day after the surgery. This was managed using Injection Transamine® (Pakistan Pharma Ltd., Pakistan), while loose faeces were observed only in one dog, i.e. Dog B1, on the 7<sup>th</sup> day, post-operatively.

**Radiographic findings:** Contrast radiography of the abdomen in a ventrodorsal view depicted normal findings in both groups; there was neither any leakage, nor marked stenosis in either group.

**Post Surgical Observation:** Healing was good in all the dogs. Healing time was in the range of 21 to 25 days. There was no visible difference in gross appearance after healing. None of the dogs suffered from peritonitis when

assessed individually (i.e. intra group comparison); however, the intra-luminal diameter was significantly reduced in each group A & B (P 0.000), respectively, before and after the surgery (Table 1).

Inter-group comparisons regarding change in intraluminal diameters between Groups A and B were non-significant.

**Suturing time:** When intestinal anastomosis suturing times between Groups A and B were compared, a significant difference was found in the duration of operation (P 0.0002). On the whole, stapled suturing technique requires an average of 10 minutes less than the conventional hand-sewn method (Table 2).

**Table 1. Pre-operative and post-operative luminal diameter measurements of the jejunum in Groups A and B.**

GROUP A (Conventional hand-sewn intestinal anastomosis)			GROUP B (Stapled suturing style using EEA stapler)				
Dog No.	Pre-operative luminal diameter (cm)	Post-operative luminal diameter (cm)	Change in luminal diameter (cm)	Dog No.	Pre-operative luminal diameter (cm)	Post-operative luminal diameter (cm)	Change in luminal diameter (cm)
A1	2.2	1.9	0.3**	B1	2.1	1.9	0.2**
A2	2.4	2.1	0.3**	B2	2.2	1.9	0.3**
A3	2.1	1.8	0.3**	B3	1.9	1.6	0.3**
A4	2.3	1.9	0.4**	B4	2.4	2.1	0.3**
A5	2.1	1.9	0.3**	B5	2.2	1.9	0.3**
A6	2.1	Expired	-	B6	2.0	1.7	0.3**
Change in luminal diameter (Mean Value in cm)		0.3		Mean Value (cm)		0.28	
Standard Error (S.E.)		0.026		Standard Error (S.E.)		0.02	
t-test value		11.62		t-test value		17	
Degree of freedom (d.f.)		5		Degree of freedom (d.f.)		5	
P Value		0.000**		P Value		0.000**	

Inference:

Each group, A and B, respectively, showed a highly significant decrease in intra-luminal diameters when assessed before and after the surgeries (P 0.000). Asterisks mark high significance.

Inter-group comparisons (i.e. Groups A vs B) were non-significant.

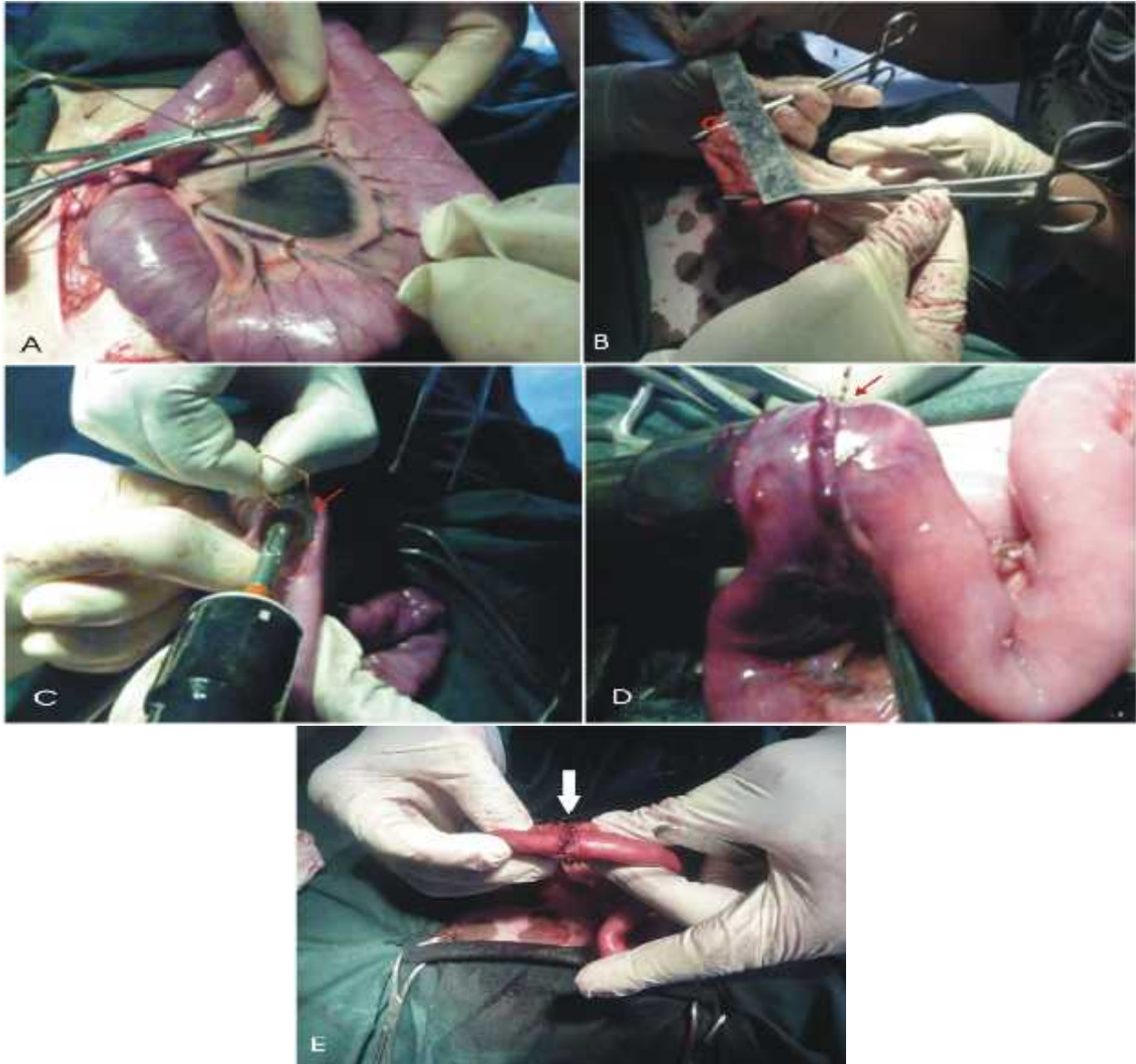
**Table 2. Comparison of Suturing Time Taken for Anastomosis in Groups A and B, i.e. Suturing Time for Conventional vs. Stapled Technique.**

Group A (Conventional)		Group B (Stapled)	
Dog No.	Operation time (minutes)	Dog No.	Operation time (minutes)
A1	54	B1	46
A2	57	B2	44
A3	55	B3	42
A4	52	B4	40
A5	50	B5	49
A6	58	B6	45
Mean Value (min.)	54.3	Mean Value (min.)	44.3**

Standard Error (S.E.)	1.23	Standard Error (S.E.)	1.28
Degree of Freedom	10	Degree of Freedom	10
P Value		0.0002**	

Inference:

Comparison of mean suturing times between the two groups yielded a highly significant difference of 10 minutes (P 0.0002) for Group B, i.e. stapled anastomosis takes lesser time as compared to the conventional hand-sewn method.



**Figure 1.** Surgical Techniques elaborating jejunal segment exteriorization and end-to-end anastomosis techniques viz. traditional, hand-sewn and circular surgical stapling methods. A, Exteriorization of the jejunal segment (arrow), and ligation of mesenteric blood vessels for a traditional hand-sewn anastomosis. B, Removal of a measured part of the jejunum (arrow). C, Insertion of anvil through enterotomy incision (arrow) for a stapled anastomosis. D, Closure of anvil of stapler for a stapled anastomosis. E, Completed conventionally hand-sewn anastomosis with crushing (Gambee) suture (white arrow).

## DISCUSSION

Intestinal anastomosis is currently being performed by both, the conventional hand-sewn method,

using different kinds of suturing materials and suturing patterns, and with the use of surgical staplers, as also reported by Nasir Khan *et al.* (2006). The efficacy of these anastomoses techniques has been studied widely in

terms of their effects on intra-luminal diameter, wound healing and post-operative complications. In this study, the efficacy of the two techniques of end-to-end jejuno-jejunal anastomosis were assessed on basis of changes in intra-luminal diameter, leakage or peritonitis, post-operatively, and time for suturing during the surgeries, respectively.

Surgical stapling is considered superior to the conventional hand-sewn methods (El-Bakry, 2002), since complications related to the stapling technique are uncommon; mechanical failure is quite rare and malfunction, if any, occurs only due to operator inexperience. Our findings regarding greater efficacy of staplers was in agreement with Kim *et al.*, (2012), who reported that small diameter 25 mm circular staplers provide more reliable anastomosis than large-diameter 29 mm circular staplers.

Among complications, the end-to-end intestinal anastomosis is reported to predispose the patient to stricture formation, post-operatively. The degree of stenosis/ stricture formation reportedly remains the same with both the conventional hand-sewn and stapled anastomosis, and that there is no significant difference in stricture formation between the two techniques, as documented upon, by Coolman *et al.* (2000) and Fingerhut *et al.* (1995). Further investigations by Moran (2006) revealed that stricture formation is more common with the use of circular staplers than conventional hand-sewn method. Jaroszewski *et al.*, 2011 have reported that acceptable stricture formation does occur after application of surgical staples, however, the surgical outcome is good. Stricture formation may be influenced by the circular stapler diameter with respect to body mass index (BMI), operation method, operation time, and the presence of co-morbidity and complications (Kim KH *et al.*, 2012). Furthermore, stricture formation occurs less commonly when anastomosis is made with a single row of staples than with a double row of staples, however, single row of staples is not adequate to resist leakage due to non-linear buckling and opening of the tissue layers between two adjacent staples (Nová *ek et al.*, 2012), hence double row of staples proves more reliable and safe, whilst stricture formation is not marked if the correct diameter of stapler is employed. This was in close agreement with our findings of an insignificant difference in stricture formation between the two groups, A and B, (on inter-group comparisons), despite a highly significant decrease in intraluminal diameter within each group individually (P 0.000; Table 1), as measured before and after the surgery.

Suturing time is another parameter for assessment of efficacy of the technique. Hence, time taken for a stapled anastomosis is reported to be significantly less than the conventional hand-sewn method of anastomosis (Wrighton *et al.*, 2008), thus ascertaining comparatively faster and convenient suturing

(Jaroszewski *et al.*, 2011; Hayashibe, 2013). Stapled anastomoses can be made on an average of 8 minutes less to perform, than the hand-sewn technique (Fingerhut *et al.*, 1995). Short surgical time is desirable because it reduces the operative exposure of patient, minimizes anesthesia time and consequently reduces patient morbidity and mortality (Everett *et al.*, 2005). In the present study, our findings of decreased post-operative complications (i.e. no marked stricture formation and no significant bleeding post-operatively), better efficacy and decreased suturing time, were in agreement with the investigations of other scientists (White, 2008; Li *et al.*, 2012; Mitchell *et al.*, 2012); the suturing time for the end-to-end anastomosis was significantly less (P 0.0002) for stapled anastomosis as compared with the conventional hand-sewn method (Table 2).

Risks associated with the occurrence of complications, with respect to the application technique of end-to-end intestinal anastomosis may limit its adaptability to routine surgical practice. Among the various anastomotic techniques applied for end-to-end intestinal anastomosis, complications were reported to occur with the same frequency with both, the conventional hand-sewn method and stapled suturing technique, as reported by Lusota *et al.*, (2001), who found no significant difference in the rate of anastomotic leakage. Nonetheless, surgical staples are still considered highly efficacious since they are associated with fewer leakage risks (Choy *et al.*, 2011). However, the complication of post-operative hemorrhage was found to occur comparatively more frequently with hand-sewn method, yet, not up to a significant level (Fingerhut *et al.*, 1995). Despite superior efficacy, circular surgical EEA staplers may well be associated with minor risks of gastrointestinal bleeding, as documented upon by Offodile *et al.*, 2010. This was in close agreement of our finding of bloody stools passed by one dog after surgical stapling. Yet, other scientists report no significant differences between the conventional hand-sewn method or the stapled suturing method regarding clinical characteristics and severity of complications (Everett *et al.*, 2005; Hayashibe, 2013). The same finding was recorded in our present study, whereby, the complications of decrease in intra-luminal diameter, risks of leakage and gastrointestinal bleeding, observed in both the groups were more or less uniform; none of the groups showed marked severity in the occurrence of complications.

On the whole, although stapled suturing technique is an expensive method to be used in veterinary practice for intestinal anastomosis, however, keeping in view its efficacy and minimal post-operative complications in small animals, the economic restraints can be negotiated and the technique proves rapidly adaptable for routine clinical practice. More importantly, the stapled technique can conveniently be applied by an

average practitioner engaged in small animal practice in various parts of our country.

**Conclusion:** The stapled technique for intestinal anastomosis is more preferable than the conventional hand-sewn method because it requires less time for application which consequently reduces the surgical time and hospitalization duration, which in turn, are desirable factors to reduce patient morbidity and mortality.

**Acknowledgements:** This project led to successful completion of my M. Phil degree. Hence, as author, I express my heartfelt thanks and tribute for my parents and all of my teachers for their enlightened guidance and assistance. Fervent thanks also for my colleagues and the Surgery team at Surgery Section, UVAS, Lahore, for their moral and technical support. Lastly, I extend my special thanks for Dr. Muhammad Asad Ali who assisted me with the plagiarism scan.

## REFERENCES

- Cakabay B., B.Aksel, E.Ünal, S. Bayar, H.Kocao lu, S. Demirci and H.Akgül (2011). Evaluating esophagojejunostomy anastomosis with methylene blue. *Eur J Surg Sci*; 2: 27-31.
- Choy P.Y.G., I.P. Bissett, J.G. Docherty, B.R. Parry, A. Merrie and A. Fitzgerald (2011). Stapled versus hand sewn methods for ileocolic anastomoses. *Cochrane Database Syst Rev.*; Issue 9: CD004320.
- Coolman B.R., N. Ehrhart, G. Pijanowski, E. J. Ehrhart and S. L. Coolman (2000). Comparison of Skin Staples with Sutures for Anastomosis of the Small Intestine in Dogs. *Vet Surg*; 29: 293-302.
- El-Bakry A.A. (2002). Bowel anastomosis: A comparative study of various surgical techniques. *Saudi Med J*; 23: 1232-1236.
- Everett W.G., P.G. Friend and J. Forty (2005). Comparison of stapling and hand-suture for left-sided large bowel anastomosis. *Br J Surg*; 73: 345-348.
- Fingerhut A., J.M. Hay, A.Elhadad, F.Lacaine and Y. Flamant (1995). Supraperitoneal colorectal anastomosis: hand-sewn versus circular staples--a controlled clinical trial. *French Associations for Surgical Research. Surgery*; 118: 479-485.
- Hayashibe A. (2013). The comparison of clinical results between hand suturing and mechanical stapling for gastrojejunostomy and jejunoejunostomy after SSPD. *Int J Surg*; 11:161-163.
- Jaroszewski D.E., D.G. Williams, D.E. Fleischer, H.J. Ross, Y. Romero and K.L. Harold (2011). An early experience using the technique of transoral OrVil EEA stapler for minimally invasive transthoracic oesophagectomy. *Ann Thorac Surg*; 92(5): 1862-9.
- Kavic S.M. (2014). Long-term follow-up of a novel anastomotic device in a canine model. *Surgical Innovation*; 21(2):198-203.
- Kim K.H., M.C. Kim and G.J. Jung (2012). Risk factors associated with delayed gastric emptying after subtotal gastrectomy with Billroth-I anastomosis using circular stapler for early gastric cancer patients. *J Korean Surg Soc*; 83(5): 274-280.
- Kim M.K., J.M. Park, Y.S. Choi and K.C. Chi (2012). Smaller-diameter circular stapler has an advantage in Billroth I stapled anastomosis after laparoscopy-assisted distal gastrectomy. *J Laparoendosc Adv Surg Tech A*; 22(3):236-41.
- Li H., B. Hu, B. You, J.B. Miao, Y.L. Fu and Q.R. Chen (2012). Combined laparoscopic and thoracoscopic Ivor Lewis oesophagectomy for esophageal cancer: initial experience from China. *China Med J (Engl)*; 125(8):1376-80.
- Lustosa S.A., D. Matos, A.N. Atallah and A.A. Castro (2001). Stapled versus hand sewn methods for colorectal anastomosis surgery. *Cochrane Database Syst Rev*, 3: CD003144.
- Martel G and R.P. Boushey (2007). Stapled Small Bowel Anastomoses. *Op Tech Gen Surg*; 10:1053.
- Mitchell I.C.S., R Barber, A.C. Fischer and D.T. Schindel (2011). Experience performing 64 consecutive stapled intestinal anastomoses in small children and infants. *J Pediatr Surg*; 46:128-130.
- Moran B.J. (2006). Stapling instruments for intestinal anastomosis in colorectal surgery. *Br J Surg*; 83: 902-909.
- Nasir Khan M.U., F. Abir, W. Longo and R. Kozol. (2006). Anastomotic disruption after large bowel resection. *World J Gastroenterol*; 12: 2497-2504.
- Nováček V., T.N. Trnava, U. Klinge, R.H. Tolba, M. Staat, D.G. Bronson, A.M. Miesse, J. Whiffen and F. Turquier (2012). Finite element modelling of stapled colorectal end-to-end anastomosis: advantages of variable height stapler design. *J. Biomechanics*; 45(15): 2693-2697.
- Offodile A.C., D.L. Feingold, A. Nasar, R.L. Whelan and T.D. Arnell (2010). High Incidence of Technical Errors Involving the EEA Circular Stapler: A Single Institution Experience. *J Am Coll Surg*; 210: 331-335.
- Vella M. and P.O'Dwyer (2002). Management of intra-abdominal gastrointestinal injuries. *J Gynec Oncol*; 7: 183-186.
- White R.N. (2008). Modified functional end-to-end stapled intestinal anastomosis: technique and clinical results in 15 dogs. *J Small Anim Pract*; 49: 274-281.
- Wrighton L, JL Curtis and G Gollin, (2008). Stapled intestinal anastomoses in infants. *J Pediatr Surg*, 43: 2231-2234.