

## PROTECTIVE EFFECT OF ASTAXANTHIN IN THE LUNG INJURY CAUSED BY ISCHEMIA REPERFUSION OF THE LOWER EXTREMITIES

H. T. Akkoyun<sup>\*1</sup>, A. Uyar<sup>2</sup>, A. Ş. Bengü<sup>3</sup>, M. Bayramoglu Akkoyun<sup>4</sup>, O. Arihan<sup>5</sup> and Ö.F. Keleş<sup>2</sup>

<sup>1</sup>Siirt University, Faculty of Veterinary, Department of Physiology, 56100, Siirt, Turkey; <sup>2</sup>Van YüzüncüYil University, Faculty of Veterinary, Department of Pathology, 65100, Van, Turkey; <sup>3</sup>Bingöl University, Department of Medical Services and Technics, Vocational School of Health Services, 12000, Bingöl, Turkey; <sup>4</sup>Siirt University, Faculty of Veterinary, Department of Biochemistry, 56100, Siirt, Turkey; <sup>5</sup>Van YüzüncüYil University, Faculty of Medicine, Department of Physiology, 65100, Van, Turkey

\*Corresponding Author's e-mail: turanakkoyun@hotmail.com

### ABSTRACT

Pathological and biochemical alterations due to lower extremity (I/R) damage and protective effects of astaxanthin (AST) were investigated. Rats were divided into four groups. GI-Sham group (n=7): Anesthesia without (I/R)(2 hours); GII-I/R (n=7) : 2 hours of ischemia and 2 hours of reperfusion under anesthesia; Group III-AST (n=7): Rats were subchronically orally administered for 7 days at 125 mg/kg astaxanthin (AST) and then anesthetized (2 hours) without ischemia; GIV-I/R+AST (n=7) : 7 days prior to ischemia rats were subchronically orally administered 125 mg/kg astaxanthin (AST) and then 2 hours of ischemia and reperfusion under anesthesia; Then lung tissues were investigated for MDA, GSH and histopathology. An increase in MDA and a decrease in GSH was observed I/R administered group compared to control. Histopathological evaluations showed intense congestion in pulmonary veins and alveolar septum and partial alveolar macrophage and erythrocyte accumulation and edema was observed in lumens of some bronchioles and alveoli in the second and fourth group compared control. Second group (3.41) damage score had high significance compared to control ( $p \leq 0.001$ ). Fourth group damage score (0.92) was indifferent from control but significantly different from I/R group ( $p \leq 0.001$ ). As a result; The protective effect of AST has been demonstrated by biochemical, histopathological and immunohistochemical effects.

**Keywords:** Lung, Astaxanthin, Rat, MDA, GSH, Histopathology.

### INTRODUCTION

Lower extremity Ischemia/reperfusion (I/R) damage is a frequently encountered phenomenon in surgical interventions (Grace, P.A. 1994). Ischemia and following reperfusion triggers local and systemic damage with the involvement of free oxygen radicals and inflammatory mediators (Tekeli *et al.* 2001; Uysal *et al.* 2006). Although blood flow saves extremity from necrosis, multi organ dysfunction may progress and cause death of the patient. In general, this damage is observed in heart, kidney and lung tissue (Blaisdell *et al.* 2002; Bengisun *et al.* 1997). Following lower extremity I/R damage, lungs are targets in end-organ damage and this damage can cause very important clinical aspects. Although etiology is not clarified yet, some humoral mediators in reperfusion are blamed for this end organ damage (Fantini *et al.* 1995; İspir *et al.* 2000). Astaxanthin (ASTA; 3,3'-dihydroxy- $\beta$ ,  $\beta$ -karoten-4,4'-dion), is found in various organisms and especially in salmon, sea bream, rainbow trout, shrimp, lobster, fish eggs and algae. This lipid soluble xanthophil has strong antioxidant functions. AST scavenges single oxygen atoms as well as other free radicals and avoids or terminates peroxidation chain reactions (Gal *et al.* 2012;

Nakagawa *et al.* 1997; Oshima *et al.* 1993). AST, is a known as a perfect antiinflammatory agent since it suppresses proinflammatory cytokine and chemokine expression (Yeh *et al.* 2016). AST, is used in treatment of cardiovascular disease (Pashkow *et al.* 2008), ischemic brain injury (Shen *et al.* 2009), cataract (Wu *et al.* 2006), diabetes (Uchiyama *et al.* 2002), hepatocellular injury due to ischemia (Curek *et al.* 2010) and diabetic nephropathy (Manabe *et al.* 2008; Naito *et al.* 2004).

Aim of this study is to evaluate protective effect of AST in the lung injury caused by ischemia reperfusion of the lower extremities.

### MATERIALS AND METHODS

**Animals:** Study was conducted at Bingöl University Animal Experiments Center after approval of Bingöl University Animal Experiments Local Ethical Committee (18.11.2015 -2015/08). Twenty-eight male Wistar-albino rats weighing 250-300 grams were used at 7-8 weeks of age. Animals were kept in cages in controlled rooms with 20-22°C constant temperature and 12 hour cycles of light-dark (lights were on between 07:00-19:00; dark between 19:00-07:00). Water and standard food were given *ad libitum*. Rats were let for adaptation for one week in their

cages and experiments started after adaptation period. Feeding was ceased 12 hours before experiments whereas water was provided throughout the experimental period.

**Experimental Design:** Commercially obtained AST was subchronically administered to Sprague-Dawley rats orally. Rats were divided into four groups each containing 7 animals; Group I (Sham Group, n=7): Rats in this group was administered with anesthesia (2 hours) without ischemia-reperfusion and tissue samples were obtained. Group II (Ischemia/Reperfusion (I/R, n=7): Rats were administered with 2 hours of ischemia and following 2 hours of reperfusion under anesthesia (Bilgiç *et al.* 2018), Group III (AST), n=7): Rats in this group was administered with subchronic orally AST for 7 days at 125 mg/kg dosage and following anesthesia for 2 hours without ischemia (Gross *et al.* 2006). Group IV (Ischemia/Reperfusion (I/R) + AST (n=7): Rats in this group was administered with subchronic orally AST for 7 days at 125 mg/kg dosage, then administered with two hours of ischemia and two hours of reperfusion under anesthesia then lung tissue samples were obtained. Rats were anesthetized with 60 mg/kg i.p. ketamine hydrochloride and 10 mg/kg Xylazine i.p. Lung tissue was removed after median laparotomy, washed with PBS, stored in deep freeze (-80°C) and biochemical (MDA,GSH) and histopathology were performed.

**Preparation of tissue extract:** Tissue samples were washed with isotonic solution, dried and weighed. They were kept at -80 °C for analyses. Samples taken out from freezer were placed into tubes and Tris-buffer was added 10 times of their weight. They were disintegrated with homogenizer and placed into +4 °C freezer. Following vortex, cell membrane was lysed with ultrasonic bath in 10 s intervals for 30 s. They were centrifuged at 16000 rpm for 30 min. Supernatants were transferred into Eppendorf tubes. MDA and GSH levels were determined with such supernatants of lung tissue.

### BIOCHEMICAL ASSAYS

**Measurement of MDA Level:** 50 mg tissue sample was homogenized with 0.15 mol/L KCl solution. Homogenates were centrifuged at 1600 × g. MDA levels in tissues were determined with thiobarbituric acid (TBA) reaction according to Placer *et al.* (Placer *et al.* 1966).

**Measurement of GSH Level:** Tissue GSH levels were measured at 412 nm according to Sedlak and Lindsay (1968). Samples were precipitated with 50 % TCA and centrifuged at 1000× g for 5 minutes. Reaction mixture contained 0.5 mL supernatant, 2.0 mL EDTA (0.2 M, pH: 8.9) buffer and 0.1 mL 0.01 M DTNB. Solution was kept in room temperature for 5 minutes and then read at 412 nm with spectrophotometer.

**Total protein concentration determination:** The total protein concentration in the lung tissue homogenate was

according to Lowry (1951). Total protein concentration in lung tissue homogenate was conducted by using bovine serum albumin as standard. A standard graphic was set by using standard bovine serum albumin standard solution. Measurements were performed at 695 nm wavelength.

**Histopathological and immunohistochemical investigations:** At the end of experimental procedure all rats were necropsied and lung tissues were taken. Lung tissue samples for histopathological investigation were fixed with 10 % buffered formalin solution for 48 hours. Tissue samples were passed from alcohol series for dehydration and from xylol series for clarification then blocked in paraffin. From those blocks serial cross sections were obtained with 4 micrometers thickness by using a microtome (Leica RM 2135). Samples were stained with Hematoxyline-Eozin (H.E.) and investigated and photographed under light microscope (Nikon 80i-DS-RI2). Histopathological findings were partially modified and evaluated semi-quantitatively. Such criteria were; alveolar generation, thickening in interalveolar septum, capillary hyperemia, hemorrhage, inflammatory cell infiltration, terminal bronchiole structure, terminal bronchiole debris, respiratory bronchiole wall structure, respiratory wall debris, alveolar structure and edema in vascular wall. Its grading were done accordingly; 0=no alteration; 1=focal light alterations; 2=multifocal light alteration; 3=multifocal apparent alteration; 4=diffuse light alteration; 5=diffuse apparent alteration (Uysal *et al.* 2006). For immunohistochemical investigation slices of 4µm thickness were placed in between poly-lysinecoated slides. To show eNOS immuno reactivity, anti-eNOS primary antibodies were used and stained with Avidin-Biotin Peroxidase Complex (ABC) immunohistochemical method. Obtained slices were incubated for 2 hours at 60°C and administered with two different xylol for clarification and rehydrated with decreasing alcohol series. Finally they were remained in distilled water for 5 minutes. Slices were kept in room temperature for 20 minutes in 0.5% trypsin solution. In addition they were kept in 3% hydrogen peroxide for 5 minutes to avoid endogenous peroxidase. Slices were washed with PBS for 5 minutes 3 times and incubated at +4°C overnight after eNOS primary antibody administration. Following day, slices were washed 3 times with PBS and let for 30 min incubation with biotinylated secondary antibody. They were bound with secondary antibody Vector Elite ABC kit. They became visible by dropping diaminobenzidine (DAB chromogen) which is the coloration substance for antibody-biotin-avidin-peroxida secomplex. Background staining was done with Mayer's hematoxyline. Dehydration was performed with graded alcohol and clarification with xylol. Finally they were covered with entellan. Immunohistochemical staining intensity was evaluated by a double blind pathologist. eNOS staining

level was scored as none (-), low staining (+), moderate staining (++) and intense staining (+++).

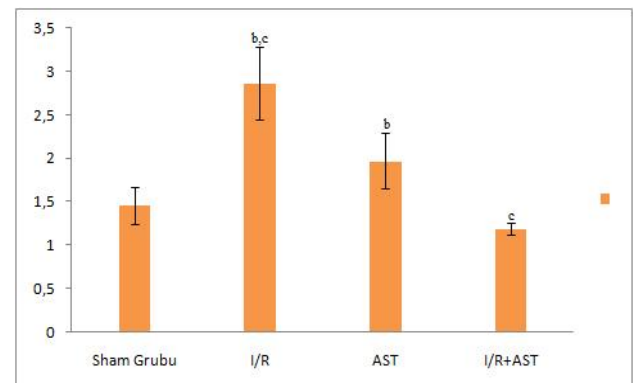
**Statistical analysis:** Statistical evaluation of the results was conducted with SPSS 20(Statistical Program-Software System) pocket program. Data were expressed as  $X \pm SEM$ . Variation analysis (ANOVA) was conducted and group comparisons were done with post-hoc Tukey' test. Statistical significance was set as  $p \leq 0.05$ .

## RESULTS

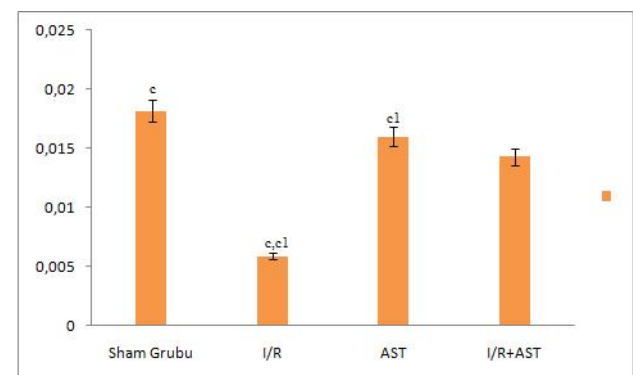
**Biochemical findings:** MDA level was increased in I/R administered group compared to control as expected. MDA level was lower in I/R+AST administered group compared to I/R group significantly ( $p \leq 0.05$ ). MDA level in AST group was found significantly lower compared to I/R group ( $p \leq 0.01$ ) (Figure1). GSH was decreased in I/R group compared to control ( $p \leq 0.05$ ). On the other hand in AST administered group, GSH value was increased compared to I/R group. This increase was found statistically significant ( $p \leq 0.05$ ) (Figure2).

**Histopathological and immunohistochemical findings:** No macroscopic alteration in lungs of rats was observed in groups. Microscopic evaluation of control group (Figure 3A) and AST administered group (Figure 3F) revealed no histopathological finding and lung parenchymatic tissue was in normal appearance. In histopathological investigation of rats in I/R group some intense histopathological findings were found. Intense congestion in pulmonary veins and inter alveolar septum was observed. In addition, there were macrophage and erythrocyte accumulation and edema in some parts of bronchioles and alveolar lumens. Hyperemia, bleeding and inflammatory cell infiltration in capillaries in inter alveolar septums were observed. Those findings showed an interstitial pneumonia with enlarged alveolar septums. In some cases perivascular and peribronchiolar mononuclear cell infiltrations were also encountered. Partial bronchiolar and alveolar epithelial cell degeneration and necrosis as well as desquamation were also observed. In addition, there was muscular hyperplasia in smooth muscle layers of some vessels and bronchioles. Due to intense exudate accumulation, congestive atelectasis with different intensities, enlargement of some alveoli in emphysematous fashion and even destruction of morphological structure due to rupture of alveolar walls were observed (Figure 3B-3D). In group administered with AST and I/R, hyperemia, hemorrhage, edema, inflammatory cell infiltration and

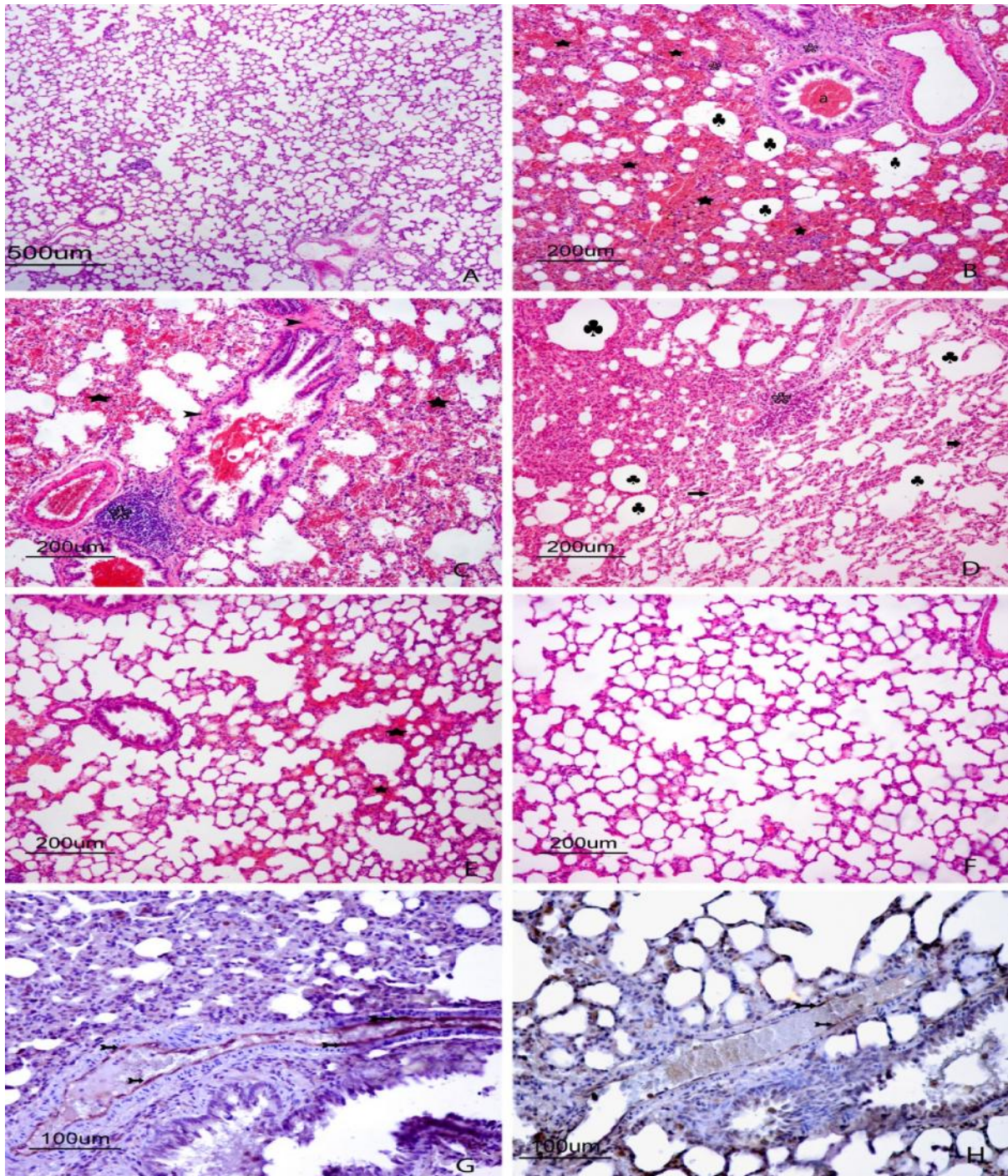
partial enlargement in inter alveolar septum were observed (Figure 3E). Such findings are quite light compared to I/R group and resembles control group in general appearance. In semi quantitative histopathological evaluation, lungs revealed no damage at 4<sup>th</sup> or 5<sup>th</sup> grade. Lowest calculated score was for control (0.69) and AST groups (0.72) without statistical difference in between. I/R group showed the highest damage score with 3.41. Difference of this group with control group gives high statistical significance ( $P \leq 0.001$ ). Damage score of concomitant AST and I/R administered group was 0.92. This value was insignificant compared to control but showed statistically significant difference with I/R group ( $P \leq 0.001$ ). Immunohistochemical evaluation of vessel endothelium showed no eNOS positive staining (-) in control group and AST administered group. In general I/R group rats showed strong eNOS staining (+++) in lung vessel endothelium (Figure 3G) whereas I/R+AST group had low eNOS staining (+) (Figure 3H).



**Figure 1. MDA levels of groups (b= $p \leq 0.01$ , c= $p \leq 0.05$ ).**



**Figure 2. GSH levels of groups (c, c1= $p \leq 0.05$ )**



**Figure 3.** A) Control Group; normal histological architecture of lung, HandE X 4. B) I/R Group; intense hemorrhage (stars), MNL infiltration in peribronchioles and interalveolar septum (°), exudate in bronchial lumen (a), emphysema in alveoli (♣), HandE X10. C) I/R Group; peribronchiolar and perivascular MNL infiltration (°), intense hemorrhage (stars) and muscular hyperplasia in bronchioles epithelial level (arrow heads), HandE X10. D) I/R Group; hemorrhage and thickening in interalveolar septum, MNL infiltration (°), emphysema (♣) and atelectasis (arrows), HandE X10. E) I/R + AST Group; nearly normal appearance in alveoli except very weak hemorrhage and edema in some interstitial area (stars), HandE X10. F) AST group; normal histological architecture of lung, HandE X10. G) I/R Group; intense eNOS positive staining in vessel endothelial cells (arrows). Immunoperoxidase X20. H) I/R + AST Group; low eNOS positive staining in vessel endothelial cells (arrows). Immunoperoxidase X20.

**Table 1. Histopathological findings of protective effect of AST on lung tissue in experimental I/R in rats.**

Parameters	Control	I/R	I/R + AST	AST
Perivascular and peribronchiolar inflammatory cell infiltration	2/8 <sup>b</sup>	8/8 <sup>a</sup>	3/8 <sup>a</sup>	2/8 <sup>b</sup>
Low	2	-	2	1
Moderate	-	2	1	1
Intense	-	6	-	-
Congestion and capillary hyperemia	2/8 <sup>b</sup>	8/8 <sup>a</sup>	3/8 <sup>a</sup>	2/8 <sup>b</sup>
Low	2	-	-	1
Moderate	-	3	3	1
Intense	-	5	-	-
Hemorrhage in interstitial	-/8 <sup>b</sup>	8/8 <sup>a</sup>	3/8 <sup>ab</sup>	-/8 <sup>b</sup>
Low	-	-	2	-
Moderate	-	2	1	-
Intense	-	6	-	-
Edema	-/8 <sup>b</sup>	8/8 <sup>a</sup>	3/8 <sup>b</sup>	-/8 <sup>b</sup>
Low	-	1	1	-
Moderate	-	3	2	-
Intense	-	4	-	-
Thickening in interalveolar septum	-/8	8/8 <sup>a</sup>	4/8 <sup>a</sup>	2/8
Low	-	-	2	2
Moderate	-	1	4	-
Intense	-	7	-	-
Emphysema in alveoli	-/8	8/8 <sup>a</sup>	4/8 <sup>a</sup>	-/8
Low	-	-	2	-
Moderate	-	3	2	-
Intense	-	5	-	-
Atelectasis in alveoli	-/8	8/8 <sup>a</sup>	4/8 <sup>a</sup>	-/8
Low	-	-	2	-
Moderate	-	3	2	-
Intense	-	5	-	-
eNOSimmunoreactivity	-/8	8/8 <sup>a</sup>	6/8 <sup>a</sup>	-/8
Low	-	-	5	-
Moderate	-	1	1	-
Intense	-	7	-	-

## DISCUSSION

I/R damage is due to free radical formation following re-oxygenation of the tissue after reperfusion of the tissue (Prem *et al.* 1999). Reactive oxygen damage may arise from more than one source and among them the most important ones are the activated neutrophils (Cetinkale *et al.* 1998; Pararajasingam *et al.* 1999; Cavanagh *et al.* 1998). Role of neutrophils in I/R damage is pronounced (İspir *et al.* 2000; Cetinkale *et al.* 1998; Lee *et al.* 1992). Most important factor for lung damage is via formation of free oxygen radicals and proteolytic enzymes released by neutrophils attached to endothelium (Berkan *et al.* 2001). Increased PMNL activity which is formed by I/R damage causes chemo attraction and infiltration of PMNL which is followed by their degranulation. After degranulation, free radical formation increases and proteases cause lung endothelium damage and augmented pulmonary capillary permeability (Nelson *et al.* 2001; Seekamp *et al.* 1993; Cohen *et al.* 1997). Recently use of substances such as superoxide dismutase,

allopurinol, catalase, mannitol, vitamin C, alpha tocopherol, pentoxyphillin in treatment of patients was tested against removing untoward effects of oxygen radicals formed during I/R and they were found effective. Those antioxidant substances activate antioxidant system and exert protective effect against end organ damage (Uysal *et al.* 2006). AST is a naturally forming carotenoid pigment and a potent biological antioxidant (Palozza *et al.* 1992). It shows oxygen radical scavenging activity and protects cell membranes, cells against lipid peroxidation and oxidative damage (Lim *et al.* 1992). In this study, lipid peroxidation was monitored with MDA measurement which arises from damage of cell membrane structures by free radicals. As expected MDA level in lung tissue was higher in I/R group compared to control and a decrease occurred in I/R+AST administered group compared to I/R group (Figure 1). In a study protective effect of AST in a kidney I/R model was investigated. They found an increase in MDA level in I/R group compared to sham and a decrease in I/R+AST group compared to I/R group (Qiu *et al.* 2015).

In another study focusing on protective effect of AST on I/R induced memory loss, MDA levels were increased in I/R group compared to sham group whereas a decrease in I/R+AST group compared to lone I/R administered group was determined (Xue *et al.* 2017). A similar increase in MDA level in lower I/R induced lung damage and a decrease due to melatonin administration was observed in another study (Uysal *et al.* 2006). In a study on rat aortic I/R investigating damage of this administration on lung damage, MDA level was increased in I/R group significantly (Kapan *et al.* 2009). Comparison of our data with those studies reveals comparable findings. When GSH level was evaluated, a decrease in I/R group compared to control ( $p \leq 0.05$ ) and an increase in this parameter in AST group compared to I/R group was determined. This increase was found statistically significant ( $p \leq 0.05$ ) (Figure 2). A study investigating effect of AST on liver I/R model also revealed a decrease in GSH in I/R group compared to control and an increase in I/R+AST group compared to I/R group (Curek *et al.* 2010). GSH level was ameliorated with AST in a study focusing on memory loss due to I/R (Xue *et al.* 2017). In another study concerning lung damage due to I/R and protective effect of silostazol and levosimendan, GSH levels were found significantly attenuated due to I/R (Önem *et al.* 2012). Our results were found similar with literature. I/R is an intensely studied subject due to its incidence however its pathogenesis and molecular pathways are not clarified completely. I/R damage occurs due to acute lung damage, acute kidney failure, shock and infection with different pathophysiological alterations in cellular, tissue and organ level. Investigation of extent of I/R damage can be conducted with histopathological evaluation of samples (Tassiopoulos *et al.* 1997; Wagner *et al.* 2002). Vascular congestion, epithelial loss and hyaline membrane formation, degenerations and necrosis in bronchiolar and alveolar cell walls, thickening in interalveolar septum, congestion in capillary walls, mononuclear cell infiltrations can be observed with light microscope (Odabaşı, D. 2006; Schnells *et al.* 1979; Pietra *et al.* 1981; Tanahashi *et al.* 1999). In addition extravascular erythrocytes, fibrinogen rich serum may fill alveolar and interstitial area thereby causing edema. Protein rich edema is caused by increased permeability in diffuse alveolar damage (Holter *et al.* 1986) and this permeability damage affects pulmonary surfactant system (Petty *et al.* 1977; Aronsen *et al.* 1996). Alveolar surfactant is activated in the presence of plasma proteins. Anomaly or loss of this surfactant is ended up with micro atelectasis in alveoli and respiratory bronchioles (Holm *et al.* 1988). Such effects occurring during ischemia-reperfusion arise due to oxidative stress caused by augmented oxygen radical production in each stage of micro circulation (Colletti *et al.* 1995). Cells can adapt to a certain level of increased oxidative stress occurring in a slow increase fashion. However when oxidative level

reaches to an intolerable level cellular function deteriorates and irreversible cell damage occurs which leads to cell death (Teoh *et al.* 2003). Lung tissue is one of the most vulnerable tissue against oxidative stress due to its special structure and function (Guo *et al.* 2007). Following I/R, formation of free oxidant radicals and inflammatory mediators initiate local and systemic damage (Grace, P.A. 1994). Although reperfusion of blood flow saves the extremity from necrosis, it may lead to multisystemic organ dysfunction and mortality. Local effects are observed in skeletal muscle and vessel endothelium whereas systemic effects are observed in especially myocardial tissue, lung and kidneys (Blaisdell *et al.* 2002). Lung tissue is the most vulnerable tissue for lower extremity I/R damage and due to occurred damage ventilator and inotropic support is needed in some cases which may even result in death (Rocker, G.M. 1997). Researchers administered some substances with antioxidant nature to minimize or prevent damage caused by I/R. In a study including 3 hours of I/R, widespread neutrophil infiltration, alveolar array disorientation, intraalveolar edema formation in lungs of I/R administered group. This serious lung damage was alleviated with dexmedetomidin administration (Küçükebe, Ö.B. 2009). In a lower extremity I/R model dexametazon and aminoguanidin administration decreased lung PNL numbers, interstitial edema and congestion compared to I/R group (Tassiopoulos *et al.* 1997). Similarly in literature melatonin was given to alleviate damage following administration of different I/R models and PNL accumulation was attenuated due to melatonin administration (Celik *et al.* 2002; Inci *et al.* 2002). In histopathological investigation of protective effect of melatonin on lower extremity I/R induced lung damage; edema, alveolar congestion, presence of MNL cells, fibrin-platelet-trombus formation, chronic inflammation and intraalveolar bleeding in lungs were ameliorated by melatonin by preventing lipid peroxidation and reducing neutrophil infiltration (Uysal *et al.* 2006). Researchers formed ischemia in lungs by adjusting a clamp on abdominal aorta and following reperfusion congestion, mononuclear cell infiltration and interstitial edema which are frequently encountered in lung damage was avoided by using aprotin (Şirin *et al.* 2001). In a study investigating protective effect of caffeic acid phenylester in lower extremity I/R damage peribronchial and perivascular leucocyte infiltration was decreased compared to I/R administered group (Çalikoğlu *et al.* 2004). Similarly ascorbic acid was also found effective in preventing increase in MNL count, interstitial edema and congestion due to I/R (Berkan *et al.* 2001). Our study focuses on protective effect of AST in lung damage due to lower extremity I/R damage. Histopathological evaluation showed that I/R group had congestion in interalveolar capillaries, alveolar macrophage and erythrocyte accumulation in some

bronchiole and alveolar lumens, interstitial and alveolar edema, perivascular and peribronchiolar MNL cell infiltration, hyperemia in capillaries of inter alveolar septum, interstitial pneumonia with enlarged inter alveolar septum due to bleeding and inflammatory cellular infiltrations, degeneration and necrosis in some bronchioles and alveolar epithelial cells and desquamation with necrosis, muscular hyperplasia in vessel and bronchiolar smooth muscle layers, congestive atelectasis in different intensities due to heavy exudate accumulation in interstitial area and also disruption of normal morphological appearance of some alveolar in an emphysematous fashion was observed. However in I/R+AST group an alleviation of this damage was observed. Hyperemia in capillaries of some inter alveolar septum and inflammatory cellular infiltrations and an enlargement in some of the inter alveolar septum was observed but those findings was quite low compared to I/R group and resembling control group. Our results show similar findings with literature mentioned above when those histopathological findings and damage scores are evaluated together (Weiss *et al.* 1989; Faust *et al.* 1988; Feller *et al.* 1989).

**Conclusion:** The protective effect of AST has been demonstrated by biochemical, histopathological and immunohistochemical effects.

**Ethical Considerations:** Study was approved by Animal Experiments Local Ethical Committee (18.11.2015 - 2015/08, Decision number: 08/02 ).

**Conflict of Interest:** Authors declare no conflict of interest.

## REFERENCES

- Aronsen, E.L., and J.M. Shannon (1996). Epithelial injury and repair, in: Ewans T.W, Haslett C (eds). ARDS: Acute Respiratory Distress Syndrome in Adults. 197-312.
- Bengisun, U., C. Köksoy, J.S. Bengisun, G. Bayraktaroglu, A. Camur, and N. Aras (1997). Ischemia and reperfusion injury: prevention of pulmonary hypertension and leukosequestration following lower limb ischemia. Prostaglandins, leukotrienes and essential fatty acids. 56(2): 117-120.
- Berkan, Ö., E. Yıldız, N. Katrancıoğlu, and İ. Günay (2001). Alt ekstremite iskemi reperfüzyona bağlı gelişen akciğer hasarında askorbik asidin etkisi. Türk Göğüs Kalp Damar Cer Derg. 9(4): 238-241.
- Bilgiç, M.İ., G. Altun, H. Çakıcı, K. Gideroğlu, G. Saka (2018). The protective effect of Montelukast against skeletal muscle ischemia reperfusion injury: An experimental rat model. Ulusal travma ve acil cerrahi dergisi= Turkish J trauma and Emergency Surgery. 24(3):185-190.
- Blaisdell, F.W. (2002). The pathophysiology of skeletal muscle ischemia and the reperfusion syndrome: a review. Cardiovascular surgery.10(6): 620-630.
- Cavanagh, S.P., M.J. Gough, and S. Homer-Vanniasinkam (1998). The role of the neutrophil in ischaemia-reperfusion injury: potential therapeutic interventions. Cardiovascular surgery. 6(2): 112-118.
- Cohen, S.M, F.A. Siddiqi , B. Darakchiev, G.A. Fantini, R.J. Hariri, P.S. Barie (1997). Attenuation of acute lung injury caused by hind-limb ischemia-reperfusion injury by butyrolactone anti-inflammatory agent FL 1003. J Trauma. 43(2): 247-52.
- Colletti, L.M., S.L. Kunkel, A. Walz, M.D. Burdick, R.G. Kunkel, C.A. Wilke, and R.M. Strieter (1995). Chemokine expression during hepatic ischemia / reperfusion-induced lung injury in the rat. The role of epithelial neutrophil activating protein. J. Clinical Investigation. 95(1): 134.
- Curek, G.D., A. Cort, G. Yucel, N. Demir, S. Ozturk, G.O. Elpek, and M. Aslan (2010). Effect of astaxanthin on hepatocellular injury following ischemia / reperfusion. Toxicology. 267(1): 147-153.
- Çalikoğlu, M., A. Ünlü, N. Sucu, S. Aktaş, L. Tamer, and İ. Çalikoğlu (2004). Periferik İskemi Reperfüzyonun Akciğerdeki Nitrozatif Etkileri Ve “Caffeic Acid Phenethyl Ester” İn Koruyucu Rolü. Tüberküloz Ve Toraks Dergisi. 52: 218-33.
- Celik, H., A. Ayar, N. Tug, M. Simsek, I. Ozercan, G. Cikum, and I. Bildirici (2002). Effects of melatonin on noncardiogenic pulmonary edema secondary to adnexial ischemia-reperfusion in guinea pig. Neuroendocrinology Letters. 23(2): 115-118.
- Çetinkale, O., L. Bilgic, M. Bolayirli, R. Sengul, F. Ayan, and G. Burcak (1998). Involvement of neutrophils in ischemia-reperfusion injury of inguinal island skin flaps in rats. Plastic and Reconstructive Surgery. 102(1): 153-160.
- Fantini, G.A. and M.S. Conte (1995). Pulmonary failure following lower torso ischemia: clinical evidence for a remote effect of reperfusion injury. The American Surgeon. 61(4): 316-319.
- Faust, K.B., V. Chiantella, J. Vinten-Johansen, and J.H. Meredith (1988). Oxygen-derived free radical scavengers and skeletal muscle ischemic / reperfusion injury. The American surgeon. 54(12): 709-719.
- Feller, A.M., A.C. Roth, R.C. Russell, B. Eagleton, H. Suchy, and N. Debs (1989). Experimental evaluation of oxygen free radical scavengers in

- the prevention of reperfusion injury to skeletal muscle. *Annals of plastic surgery*. 22(4): 321-331.
- Gal, A.F., S. Andrei, C. Cernea, M. Taulescu, and C. Catoi (2012). Effects of astaxanthin supplementation on chemically induced tumorigenesis in Wistar rats. *Acta Veterinaria Scandinavica*. 54(1): 50.
- Grace, P.A (1994). Ischaemia-reperfusion injury. *British J. Surgery*. 81(5): 637-647.
- Gross, G.J., S.L. Hazen, and S.F. Lockwood (2006). Seven day oral supplementation with Cardax TM (disodium disuccinate astaxanthin) provides significant cardioprotection and reduces oxidative stress in rats. *Molecular and cellular biochemistry*. 283(1-2): 23-30.
- Guo, R.F., and P.A. Ward (2007). Role of oxidants in lung injury during sepsis. *Antioxidants redox signaling*. 9(11): 1991-2002.
- Holm, B.A., G. Enhorning, and R.H. Notter (1988). A biophysical mechanism by which plasma proteins inhibit lung surfactant activity. *Chemistry and Physics of Lipids*. 49(1-2): 49-55.
- Holter, J.F., J.E. Weiland, E.R. Pacht, J.E. Gadek, and W.B. Davis (1986). Protein permeability in the adult respiratory distress syndrome. Loss of size selectivity of the alveolar epithelium. *J. Clinical Investigation*. 78(6):1513.
- Inci, I., D. Inci, A. Dutly, A. Boehler, and W. Weder (2002). Melatonin attenuates posttransplant lung ischemia-reperfusion injury. *The Annals of thoracic surgery*. 73(1): 220-225.
- İspir, S., S. Akgün, K. Ak, Ü. Zeybek, M. Aydın, A. Civelek, A. Tekeli, and A. Çobanoğlu (2000). Akut alt ekstremite iskemi / reperfüzyon hasarının akciğer serbest oksijen radikalleri üzerine olan etkisi. *Türk Göğüs Kalp Damar Cer Derg*. 8: 629-631.
- Kapan, S., I. Kiris, A. Kılbas, I. Altuntas, and N. Karahan (2009). Eritropoietinin sıçan aortik iskemi-reperfüzyonunda akciğer hasarı üzerine etkisi. *Turkish J Thorac Cardiovasc Surg*. 17(2): 110-6.
- Küçükebe, Ö.B. (2009). Deneysel alt ekstremite iskemi reperfüzyon modelinde deksmedetomidinin akut akciğer hasarı üzerindeki etkililiğinin araştırılması, *Uzmanlık Tezi, Dokuz Eylül Üniversitesi Tıp Fakültesi. İzmir*.
- Lee, C., C.L. Kerrigan, and J.M. Tellado (1992). Altered neutrophil function following reperfusion of an ischemic myocutaneous flap. *Plastic and reconstructive surgery*. 89(5): 916-923.
- Lim, B.P., A. Nagao, J. Terao, K. Tanaka, T. Suzuki, and K. Takama (1992). Antioxidant activity of xanthophylls on peroxy radical-mediated phospholipid peroxidation. *Biochimica et Biophysica Acta (BBA)-Lipids and Lipid Metabolism*. 1126(2): 178-184.
- Lowry, O.H., N.J. Rosebrough, A.L. Farr, and R.J. Randall (1951). Protein measurement with the Folin phenol reagent. *J. Biological Chemistry*. 193(1): 265-275.
- Manabe, E., O. Handa, Y. Naito, K. Mizushima, S. Akagiri, S. Adachi, and T. Yoshikawa (2008). Astaxanthin protects mesangial cells from hyperglycemia-induced oxidative signaling. *J Cell Biochem*. 103(6):1925.
- Naito, Y., K. Uchiyama, W. Aoi, G. Hasegawa, N. Nakamura, N. Yoshida, and T. Yoshikawa (2004). Prevention of diabetic nephropathy by treatment with astaxanthin in diabetic db/db mice. *Biofactors*. 20(1): 49-59.
- Nakagawa, K., S.D. Kang, D.K. Park, G.J. Handelman, and T. Miyazawa (1997). Inhibition of beta-carotene and astaxanthin of NADPH-dependent microsomal phospholipid peroxidation. *J Nutr Sci Vitaminol (Tokyo)*. 43(3): 345-55.
- Nelson, K., B. Herndon, and G. Reisz (1991). Pulmonary effects of ischemic limb reperfusion: Evidence for a role for oxygen-derived radicals. *Critical care medicine*. 19(3): 360-363.
- Odabaşı, D. (2006). L-karnitin'inrtaortikiskemi-reperfüzyon modelinde akciğer ve endotel hasarı üzerine etkisi, *Süleyman Demirel Üniversitesi Tıp Fakültesi.İsparta*.
- Oshima, S., F. Ojima, H. Sakamoto, Y. Ishiguro, and J. Terao (1993). Inhibitory effect of beta-carotene and astaxanthin on photosensitized oxidation of phospholipid bilayers. *J Nutr Sci Vitaminol (Tokyo)*. 39(6): 607- 15.
- Önem, G., M. Saçar, H. Aybek, E. Kocamaz, F. Adalı, K.G. Saçkan, and A. Baltarlı (2012). Protective effects of cilostazol and levosimendan on lung injury induced by lower limb ischemia-reperfusion. *Turk J Thorac Cardiovasc Surg*. 20: 577-83.
- Palozza, P., and N.I. Krinsky (1992). Astaxanthin and canthaxanthin are potent antioxidants in a membrane model. *Archives of Biochemistry and Biophysics*. 297(2): 291-295.
- Pararajasingam, R., M.L. Nicholson, P.R.F. Bell, and R.D. Sayers (1999). Non-cardiogenic pulmonary oedema in vascular surgery. *European J. Vascular and Endovascular Surgery*. 17(2): 93-105.
- Pashkow, F.J., D.G. Watumull, and C.L. Campbell (2008). Astaxanthin: a novel potential treatment for oxidative stress and inflammation in cardiovascular disease. *Am J Cardiol*. 101(10A): 58D-68D.
- Petty, T.L., O.K. Reiss, G.W. Paul, G.W. Silvers, and N.D. Elkins (1977). Characteristics of Pulmonary Surfactant in Adult Respiratory Distress Syndrome Associated with Trauma and Shock 1-



3. American Review of Respiratory Disease. 115(3): 531-536.
- Pietra, G.G., J.R. Rüttner, W. Wüst, and W. Glinz (1981). The lung after trauma and shock--fine structure of the alveolar-capillary barrier in 23 autopsies. *The J. Trauma*. 21(6): 454-462.
- Placer, Z.A., L.L. Cushman, and B.C. Johnson (1966). Estimation of product of lipid peroxidation (malonyl dialdehyde) in biochemical systems. *Analytical biochemistry*. 16(2): 359-364.
- Prem, J.T., M. Eppinger, G. Lemmon, S. Miller, D. Nolan, and J. Peoples (1999). The role of glutamine in skeletal muscle ischemia / reperfusion injury in the rat hind limb model. *The American J. Surgery*. 178(2): 147-150.
- Qiu, X., K. Fu X. Zhao, Y. Zhang, Y. Yuan, S. Zhang, X. Gu, and H. Guo (2015). Protective effects of astaxanthin against ischemia / reperfusion induced renal injury in mice. *J. Translational Medicine*. 13(1): 28.
- Rocker, G.M. (1997). Ischaemia / reperfusion, inflammatory responses and acute lung injury. *Thorax*. 52(10): 841.
- Seekamp, A., M.S. Mulligan, G.O. Till, and P.A. Ward (1993). Requirements for neutrophil products and L-arginine in ischemia-reperfusion injury. *The American J. Pathology*. 142(4): 1217.
- Schnells, G., W.H. Voigt, H. Redl, G. Schlag, and A. Glatzl (1979). Electron-microscopic investigation of lung biopsies in patients with post-traumatic respiratory insufficiency. *Acta chirurgica Scandinavica. Supplementum*. 499: 9-20.
- Sedlak, J., and R.H. Lindsay (1968). Estimation of total, protein-bound, and nonprotein sulfhydryl groups in tissue with Ellman's reagent. *Analytical Biochemistry*. 25: 192-205.
- Shen, H., C.C. Kuo, J. Chou, A. Delvolve, S.N. Jackson, J. Post, S.W. Amina, J.H. Barry, Y. Wang, and K.H. Brandon (2009). Astaxanthin reduces ischemic brain injury in adult rats. *The Faseb J*. 23(6):1958-68.
- Şirin, H., O. Sarıbülbül, M. Cerrahoğlu, Ö. Aksoy, A. Baltalarlı, and M. Saçar (2001). Alt ekstremité iskemi reperfüzyonunun yol açtığı pulmoner hasarda aprotinin'in koruyucu etkinliđi. *Türk Göğüs Kalp Damar Cer Derg*. 9(4): 233-237.
- Tekeli, A., S. Akgün, A. Civelek, S. İşbir, K. Ak, G. Demirtaş, S. Şirvancı, S. Arbak, İ. Yaylım, A. Çobanođlu (2001). Alt ekstremité iskemi reperfüzyonu sonucunda gelişen akciđer hasarının önlenmesinde farklı bir ajan: FK 506 (takrolimus). *Türk Göğüs Kalp Damar Cer Derg*. 9(4): 242-246.
- Tassiopoulos, A.K., R.E. Carlin, Y. Gao, A. Pedoto, C.M. Finck, S.K. Landas, and D.J. McGraw (1997). Role of nitric oxide and tumor necrosis factor on lung injury caused by ischemia / reperfusion of the lower extremities. *J. Vascular Surgery*. 26(4): 647-656.
- Tanahashi, Y., I. Takeyoshi, M. Aiba, S. Ohwada, K. Matsumoto, and Y. Morishita (1999). The effects of FK409 on pulmonary ischemia-reperfusion injury in dogs. *Transplant international*. 12(6): 402-407.
- Teoh, N.C., and G.C. Farrell (2003). Hepatic ischemia reperfusion injury: pathogenic mechanisms and basis for hepatoprotection. *J. Gastroenterology and Hepatology*. 18(8): 891-902.
- Uchiyama, K., Y. Naito, G. Hasegawa, N. Nakamura, J. Takahashi, and T. Yoshikawa (2002). Astaxanthin protects beta-cells against glucose toxicity in diabetic db/db mice. *Redox Rep*. 7(5): 290-3.
- Uysal, A., O. Burma, İ. Akar, K.K. Özsin, A. Rahman, B. Üstündađ, and H.İ. Özercan (2006). Alt ekstremité iskemi reperfüzyonunun yol açtığı akciđer hasarında melatoninin koruyucu etkinliđi. *Türk Göğüs Kalp Damar Cer Derg*. 14(4): 308-314.
- Wagner, F.M., A.T. Weber, K. Ploetze, F. Schubert, S. Pfeiffer, S. Albrecht, and S. Schueler (2002). Do vitamins C and E attenuate the effects of reactive oxygen species during pulmonary reperfusion and thereby prevent injury?. *The Annals of thoracic surgery* 74(3): 811-818.
- Weiss, A.P.C., L.A. Carey, M.A. Randolph, J.R. Moore, and A.J. Weiland (1989). Oxygen radical scavengers improve vascular patency and bone-muscle cell survival in an ischemic extremity replant model. *Plastic and reconstructive surgery*. 84(1): 117-123.
- Wu, T.H., J.H. Liao, W.C. Hou, F.Y. Huang, T.J. Maher, and C.C. Hu (2006). Astaxanthin protects against oxidative stress and calcium-induced porcine lens protein degradation. *J Agric Food Chem*. 54(6): 2418-23.
- Xue, Y., Z. Qu, J. Fu, J. Zhen, W. Wang, Y. Cai, and W. Wang (2017). The protective effect of astaxanthin on learning and memory deficits and oxidative stress in a mouse model of repeated cerebral ischemia/reperfusion. *Brain Research Bulletin*. 131: 221-228.
- Yeh, P.T., H.W. Huang, C.M. Yang, W.S. Yang, and C.H. Yang (2016). Astaxanthin inhibits expression of retinal oxidative stress and inflammatory mediators in streptozotocin-induced diabetic rats. *Plos One*, 11(1): e0146438.