

SINGLE-DOSE ORAL TOXICITY AND ACUTE DERMAL IRRITATION OF STEAMED AND DRIED GINGER EXTRACT IN RAT AND WHITE RABBIT

Jae Young Kim¹, and Jae-Suk Choi^{2*}

¹Swine Science and Technology Center, Gyeongnam National University of Science and Technology, Jinju, Gyeongnam, 52725, Republic of Korea

²Division of Bioindustry, College of Medical and Life Sciences, Silla University, 140, Baegyong-daero 700 beon-gil, Sasang-gu, Busan, 46958, Republic of Korea

*Corresponding author E-mail: jsc1008@silla.ac.kr

ABSTRACT

The objective of this study was to determine the acute oral toxicity of steamed and dried ginger (*Zingiber officinale* Roscoe, Zingiberaceae) extract (SDGE) in female and male Sprague-Dawley (SD) rats at doses of 0 and 5,000 mg/kg body weight. After a single oral dose of SDGE, no treatment-related mortalities were observed within 14 days of treatment up to 5,000 mg/kg, which is 2.5 times the limited dosage for rodents of both sexes. No SDGE-related changes in body weight, clinical signs, or necropsy and histopathological findings were detected. The results suggest that SDGE is non-toxic in rats. To determine the potential utility of SDGE in dermal applications, we investigated the acute dermal irritation potential of SDGE in New Zealand white rabbits. No abnormal clinical signs attributable to SDGE were detected. In the dermal irritation test, erythema, eschar, and edema formation were observed after 24 h of treatment, but the skin returned to normal after 72 h. SDGE had a dermal primary irritation index of 0.0, showing that it was a non-irritant. These results indicate that SDGE is non-toxic to the body and non-irritating to the skin, suggesting that it can be used in pharmaceutical and dermal applications with no serious toxic effects at moderate doses.

Key words: Acute oral toxicity, dermal irritation test, steamed and dried ginger extract (SDGE), *Zingiber officinale*.

INTRODUCTION

Ginger (*Zingiber officinale* Roscoe, Zingiberaceae) is a medicinal plant used globally and in traditional Korean, Chinese, and Ayurvedic medicine to treat a wide array of unrelated ailments, including pain, arthritis, rheumatism, indigestion, vomiting, dementia, fever, and viral infectious diseases including influenza, rubella and scarlatina (Ali *et al.*, 2008; Jung *et al.*, 2012; Koo *et al.*, 2012; Lee *et al.*, 2012; Jung and Park, 2013).

In Korea, ginger is found in various products and forms, including fresh, dried powder (Kwak *et al.*, 2014), sliced (Kim, 2011), and in tea (Sung *et al.*, 2003). To develop its potential as a functional food, several attempts to extract new bio-functional materials from ginger have been reported (Jung *et al.*, 2012; Koo *et al.*, 2012; Lee *et al.*, 2012; Jung and Park, 2013). However, to improve the value of ginger products, new manufacturing processes are needed, such as fermentation (Chun and Chung, 2011), steaming (or steaming and drying) (Cheng *et al.*, 2001; Kim, 2011; Lee *et al.*, 2012), aging (Lee *et al.*, 2012; Kim *et al.*, 2013a; Kim *et al.*, 2013b), roasting (Wu *et al.*, 1990), and processing (e.g., Beopje) (Kim *et al.*, 2012; Kim *et al.*, 2014).

The health benefits of heat-treated or processed ginger are reportedly superior to those of fresh ginger (Cheng *et al.*, 2001; Chun and Chung, 2011; Kim *et al.*, 2013a; Kim *et al.*, 2013b). For example, steamed and

dried ginger extract (SDGE) showed an increased anticancer potential (Cheng *et al.*, 2001). In addition, Kim *et al.* (2012) reported that SDGE had potential benefits in dermal applications, as it exerted a strong inhibitory effect against tyrosinase.

Although ginger is generally considered to be a safe herbal medicine (Weidner and Sigwart, 2000) and an effective alternative to several conventional medicines, including antiemetic drugs (Boone and Shields, 2005), it may be prudent for women to avoid using ginger or ginger extracts during pregnancy (Marcus and Snodgrass, 2005). Moreover, several minor adverse effects are associated with the use of ginger in humans. In one clinical trial, involving 12 healthy volunteers who received 400 mg ginger orally three times per day for 2 weeks, one subject reported mild diarrhea during the first 2 days of ginger pretreatment. Ginger may cause heartburn and can act as a gastric irritant at doses above 6 g. Inhalation of ginger dust may induce immunoglobulin E-mediated allergy (Chrubasik *et al.*, 2005).

SDGE is regarded as environmentally safe, without toxicity to humans or animals, at effective concentrations (Cheng *et al.*, 2001; Kim, 2011; Lee *et al.*, 2012). However, little information regarding the *in vivo* oral toxicity and dermal irritation activity of SDGE, when used as a health-promoting agent, is available for dermal or pharmaceutical formulations (Cheng *et al.*, 2001; Kim *et al.*, 2012). Therefore, we examined the potential acute oral toxicological and dermal irritation effects of SDGE

in Sprague-Dawley (SD) rats and New Zealand white (NZW) rabbits, respectively.

MATERIALS AND METHODS

Materials and reagents: The fresh ginger used in this study was purchased from a market in Busan, Korea, washed with tap water three times, and then peeled. The steamed and dried ginger (SDG) was prepared following to the method of Kim *et al.* (2012) and Nam *et al.* (2012) with slight modifications. Briefly, fresh ginger was steamed at 96°C for 3 h, followed by hot air-drying at 50°C for 24 h. These procedures were repeated six times. The yield of the SDG was about 10.5% that of fresh ginger. The SDG was milled (HJM-15100; Hansung Pulverizing Machinery Co. Ltd., Gwangju, Korea) for 10 min to produce a powder, which was then passed through a 500-mesh sieve. To extract the water-soluble components, 800 mL of distilled water was added to 200 g of sieved SDG powder, which was held at 80°C for 30 min. The extract was filtered through a paper filter (Toyo Roshi Kaisha, Tokyo, Japan) to obtain the final filtrate, which was freeze-dried for 2 days to a moisture content of ~0.8% using a freeze-dryer (EYELA FDU-2100 with DRC-1000; Tokyo Rikakikai Co. Ltd., Tokyo, Japan) to obtain SDGE. SDGE was stored at 20°C until experimentation. The yield of SDGE was ~11.9% that of the SDG powder. High-performance liquid chromatography-grade reagents (or the highest grade available) were purchased from Sigma-Aldrich Ltd. (St. Louis, MO, USA), and all solutions were mixed with ultra-pure deionized water (Millipore, Billerica, MA, USA).

Single-dose oral toxicity test: In total, 20 female and 20 male 6-week-old SD rats (SLC, Tokyo, Japan) were used after acclimatization for 5 days. Animals were housed five per polycarbonate cage under controlled conditions, with an ambient temperature of 22 ± 1°C, humidity of 40–45%, light intensity of 150–300 lx, and a 12-h light/dark cycle. The animals were fed a commercial laboratory diet (Samyang, Korea) and water *ad libitum*. All animals were fasted overnight (~18 h) before treatment and terminal necropsy. The acute oral toxicity test for SDGE was approved by the Institutional Animal Care and Use Committee (IACUC) of Silla University (Busan, Korea; no. SUACUC-2016-013). The animals were distributed into four groups of five rats upon receipt. The highest dosage used in this study was 5,000 mg/kg in a volume of 10 mL, a dose exceeding the recommended oral dose for rats (Flecknell, 1996; OECD Guidelines no. 423, 2001; KFDA Guidelines Notification no. 2009-116, 2009). Distilled water was used as the vehicle. A single oral dose was administered using a gastric gavage attached to a 5-mL syringe. Control groups were administered distilled water.

All abnormal clinical signs were recorded before and after dosing, at least twice a day, based on the functional observational battery test (Irwin, 1968; Dourish, 1987). Body weight was measured on the day of dosing (Day 0) immediately before treatment, and 7 and 14 days after dosing. To reduce the individual body weight differences of animals during treatment, body weight gains from Days 0 to 7, 7 to 14, and 0 to 14 were calculated from the measured body weights at each time.

Macroscopic evaluation of stomach: A macroscopic evaluation of the stomach was performed following the methods of Cheng *et al.* (2013) and Fahmy *et al.* (2013), with slight modifications. Briefly, the stomach and intestinal tissues of the SD rats were fixed in 10% formaldehyde immediately following sacrifice, processed for histological examination according to the conventional method, and stained with hematoxylin and eosin. The morphologies of any observed lesions were classified and recorded. First, any ulcerative lesions in the stomach were examined under a 40× magnifying lens to assess ulcer formation. Then, the number of ulcers was counted. The ulcer score was determined as follows: normal-colored stomach, 0; red coloration, 0.5; spot ulcer, 1; hemorrhagic streak, 1.5; deep ulcer, 2; and perforation, 3. The mean ulcer score for each animal was expressed as the ulcer index (Fahmy *et al.*, 2015).

Acute dermal irritation testing: Six specific-pathogen-free NZW rabbits (2.10–2.56 kg) were purchased from Samtaco Bio Korea Ltd. (Osan, Korea). Rabbits were housed individually in stainless steel cages (W 405 × L 605 × H 365 mm) and acclimated to an environmentally controlled room with a temperature of 22 ± 1°C, relative humidity of 60 ± 5%, light intensity of 150–300 lx, and a 12-h light/dark cycle. Animals were provided with water and laboratory rabbit pellet food (Agribands Purina Korea, Seongnam, Korea) *ad libitum*. The acute dermal toxicity test for SDGE was approved by the IACUC of Silla University (Busan, Korea; no. SUACUC-2016-012). The application of SDGE to intact and abraded skin at the treatment or control sites was performed according to the methods of Draize *et al.* (1944) and Choi *et al.* (2015). The day of application was designated Day 0. Rabbits underwent one 24-h SDGE treatment. The amount of SDGE was set at 0.5 mL/square (Draize *et al.*, 1944). Clinical signs were observed at least once per day throughout the experimental period. Body weight was measured on the day of animal receipt, and on Days 0, 1, and 3. The patches were removed 24 h after the treatment, and any remaining SDGE was washed away using a physiological saline solution. Macroscopic scoring of erythema, edema, bleeding, and eschar formation was performed 30 min after removing the patches and 72 h after the initial application. Edema was evaluated using the grading criteria of Draize *et al.* (1944). The erythema/eschar and edema scores at 24 and 72 h were

added and divided by 6 (the number of animals), and the sum of the mean values was divided by 4, the product of the number of application sites and the number of observations used to calculate the primary irritation index (PII). The dermal irritation potential was evaluated using the PII, and the ability of SDGE to cause irritation was classified as follows: non-irritant, 0.0–0.5; mild, 0.6–2.0; moderate, 2.1–5.0; and severe, 5.1–8.0. In addition, any clinical signs observed after SDGE treatment were considered (OECD guideline, no. 404).

RESULTS

Acute oral toxicity of SDGE: No SDGE-related mortalities were recorded up to 5,000 mg/kg in the treated groups of both female and male rats. All SDGE-treated rats survived for the experimental period of 14 days, and all rats were subjected to the terminal necropsy. No SDGE treatment-related clinical signs were recorded

up to 5,000 mg/kg in the female or male treatment groups. No meaningful changes in body weight were detected in any SDGE-treated rats compared with the controls (Table 1).

Macroscopic evaluation of stomach: No SDGE treatment-related red coloration or ulcers were recorded in the female or male treatment groups receiving 5,000 mg/kg (Fig. 1). Therefore, the mean ulcer score and ulcer index of SDGE were 0.0 and 0.0, respectively.

Acute dermal irritation of SDGE: No mortality, clinical signs, or significant body weight changes attributable to the application of SDGE in any animals were observed during the experimental period (data not shown). No erythema, eschar, or edema was observed at the SDGE treatment or control site in any animals tested after 24 and 72 h of treatment (Table 2; Fig. 2). The PII of SDGE was determined to be 0.0; therefore, it was classified as a non-irritant in this acute dermal irritation test.

Table 1. Table 1. Body weights of SDGE-treated SD rats (unit, g).

Sex	Dose (mg/kg)	Days after dosing			Body weight gain		
		0	7	14	0-7	7-14	0-14
Male	0	198.7±8.72	235.8±11.07	295.0±8.19	37.1±7.42	59.2±9.85	96.3±9.14
	5,000	202.3±6.34	238.1±10.79	294.6±11.50	35.8±6.76	56.5±4.82	92.3±8.52
Female	0	162.6±2.39	183.5±8.73	214.0±12.39	20.9±7.07	30.5±5.93	52.0±8.21
	5,000	159.7±4.71	185.7±15.72	218.3±6.86	26.0±8.50	32.6±8.29	58.6±9.30

Mean ± standard deviation, n = 5.

Table 2. Changes in body weight of SDGE-treated NZW rabbits.

	Sex	Animal number	Hours after application (g)		Gains
			0	72	
Test material	Female	1	2563.7	2786.4	222.7
		2	2351.4	2541.6	190.2
		3	2208.6	2361.5	152.9
		4	2207.3	2385.7	178.4
		5	2365.4	2487.4	122.0
		6	2104.5	2341.5	237.0

Table 3. Skin reaction grades and indices after SDGE application to NZW rabbits.

Evaluation of irritation																	
Site		Control								Treatment							
		Intact				Abraded				Intact				Abraded			
ID	Response Time ^{a)}	Erythema (Es) ^{b)}		Edema		Erythema (Es)		Edema		Erythema (Es)		Edema		Erythema (Es)		Edema	
		24	72	24	72	24	72	24	72	24	72	24	72	24	72	24	72
1		0	0	0	0	0	0	0	0	0	0 (Es)	0	0	0	0 (Es)	0	0
2		0	0	0	0	0	0	0	0	0	0 (Es)	0	0	0	0 (Es)	0	0
3		0	0	0	0	0	0	0	0	0	0 (Es)	0	0	0	0 (Es)	0	0
4		0	0	0	0	0	0	0	0	0	0 (Es)	0	0	0	0 (Es)	0	0
5		0	0	0	0	0	0	0	0	0	0 (Es)	0	0	0	0 (Es)	0	0
6		0	0	0	0	0	0	0	0	0	0 (Es)	0	0	0	0 (Es)	0	0

Total	0	0	0	0	0	0	0	0	0	0	0	0	0	0	0	0
Mean	0	0	0	0	0	0	0	0	0	0	0	0	0	0	0	0
Sum of Means	0.00								0.00							
PII ^{c)}	0.00								0.00							

^{a)} Hours after treatment; ^{b)} Es, eschar formation; ^{c)} PII = sum/4

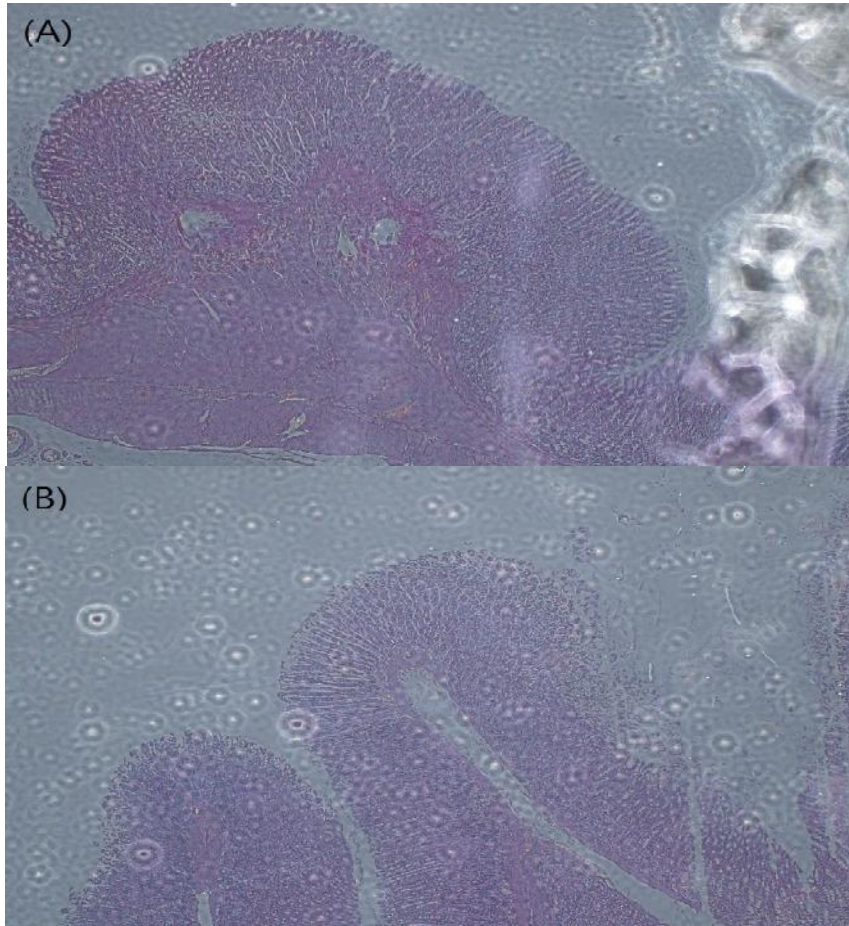


Fig. 1. Stomach morphology of Sprague-Dawley rats treated with steamed and dried ginger (*Zingiber officinale* Roscoe, Zingiberaceae) extract (SDGE) after 14 days. The photomicrographs of hematoxylin and eosin-stained tissue were imaged at a magnification of 40×. A: Male. B: Female.




Fig. 2. Skin reaction after dermal administration of SDGE (0.5 mL/square) on specific-pathogen-free New Zealand white rabbits. A: Skin reaction 24 h after treatment. B: Skin reaction 72 h after treatment, T: SDGE-treated skin, C: control (distilled water) skin.

DISCUSSION

The main pharmacological actions of ginger and ginger extracts include immunomodulatory, antitumorigenic, anti-inflammatory, antiapoptotic, antihyperglycemic, antilipidemic, and antiemetic actions. Ginger has strong antioxidant activity and may either mitigate or prevent free radical generation. It is considered to be a safe herbal medicine with only a few, non-significant adverse side effects (Ali *et al.*, 2008; Bae and Kim, 2011).

Various processing techniques have been applied to ginger, including fermentation (Chun and Chung, 2011), steaming (or steaming and drying) (Cheng *et al.*, 2001; Kim, 2011; Lee *et al.*, 2012), aging (Lee *et al.*, 2012; Kim *et al.*, 2013a; Kim *et al.*, 2013b), and roasting (Wu *et al.*, 1990), in an attempt to improve its pharmacological effects, stability, and overall acceptance (including taste and scent) while alleviating mild adverse effects.

Steaming, or steaming and drying, is a common processing technique used in oriental herbal medicine to improve the functionality of an herbal medicine. For example, repeated steaming and drying is used to process black ginseng (Shin, 2008) and *Platycodon grandiflorum* (Yang *et al.*, 2014), to improve their pharmacological effects. Recently, a steaming and drying procedure was adapted for ginger. According to Kim *et al.* (2012), steaming was performed at 115–130°C for 20–50 min, and drying was performed at 50–70°C for 12–24 h. These procedures were repeated six to seven times. The SDGE (final concentration, 5 mg/mL) exhibited a skin-whitening effect via a strong inhibitory effect on tyrosinase.

Ginger is generally considered to be a safe herbal medicine (Weidner and Sigwart, 2000). According to Weidner and Sigwart (2000), the ginger preparation Eurovita Extract 33, administered to pregnant rats during the period of organogenesis, showed no maternal or developmental toxicity at daily doses of up to 1,000 mg/kg body weight. Conversely, Wilkinson (2000) reported some adverse effects of ginger in pregnant rats. Ginger tea (15, 20, or 50 g/L) was administered via the drinking bottles of pregnant SD rats from Days 6 to 15 of gestation. The rats were sacrificed on Day 20. No maternal toxicity was observed, but embryonic loss in the treatment group was double that of the control. In a study of the acute toxicity of ginger, an 80% ethanol ginger extract was well tolerated orally in male albino Swiss mice up to a dose of 2.5 g/kg, with no mortality or side effects except mild diarrhea in two animals. However, doses of 3.0 and 3.5 g/kg of the extract resulted in mortalities of 10–30% and all mice died due to involuntary contractions of skeletal muscle within 72 h of administration. Other symptoms included gastrointestinal spasm, hypothermia, diarrhea, and anorexia (Mascol *et*

al., 1989). In addition, acute toxicity of ginger was reported (Anonymous, 2003) after administering an 80% ethanol extract in mice. At 2.5 g/kg, no mortality was observed, although two out of ten animals experienced mild diarrhea. However, doses of 3 and 3.5 g/kg resulted in mortalities of 20 and 30%, respectively, within 72 h of administration. The acute oral dose at which 50% mortality is observed (LD₅₀) in rats, and the acute dermal LD₅₀ in rabbits of ginger oil, exceeded 5 g/kg body weight (Anonymous, 2003). In addition, some minor adverse effects are associated with the use of ginger in humans, including mild diarrhea, heartburn, and gastric irritation (Chrubasik *et al.*, 2005).

In this study, No SDGE treatment-related mortalities, clinical signs, or abnormal necropsy findings were recorded up to 5,000 mg/kg (i.e., 2.5 times 2,000 mg/kg; the limited dosage in rodents) in the male or female treatment groups (Table 1). The weight gain results were consistent with age-related weight gain observations, showing no toxic effects (Choi *et al.*, 2012). In general, when toxic effects are observed, body weight loss or death occurs. Because such outcomes were not observed in this study, we deemed SDGE to be safe. The Globally Harmonized System of Classification and Labeling of Chemicals (2011) classifies compounds into five toxicity categories based on the amount of ingested material that proves toxic: 2,000–5,000 mg/kg, potentially harmful; 300–2,000 mg/kg, harmful; 50–300 mg/kg, toxic; 5–50 mg/kg, fatal; and <5 mg/kg, fatal. In this study, no toxic effect was observed at a concentration of 5,000 mg/kg; therefore, SDGE is considered to be safe under this classification. At Day 14 following the single-dose administration, all animals survived and no abnormal necropsy findings were observed. In accordance with the Korea Food and Drug Administration recommendation (2012) that histological examinations be performed only after abnormal necropsy findings, histological examination of the organs was not performed.

Ginger has been reported to stimulate gastric juice secretion and promote digestion when used as a stomachic (Seo *et al.*, 2003). According to Kim *et al.* (2012), ginger and processed ginger extracts inhibited HCl-ethanol-induced gastritis in rats. Furthermore, gastroprotective (Al-Yahya *et al.*, 1989), antigastric, and anti-ulcerative (Yang *et al.*, 1992) effects of ginger extract have been reported. Conversely, only minor adverse effects are associated with the use of ginger in humans, including mild diarrhea, heartburn, and gastric irritation (Chrubasik *et al.*, 2005). Therefore, we performed a macroscopic evaluation of the stomach in the 5,000 mg/kg SDGE treatment groups. No SDGE treatment-related red coloration or ulcers were recorded, and the mean ulcer score and ulcer index of SDGE were 0.0 and 0.0, respectively, in both female and male SD rats

(Fig. 1). Therefore, SDGE does not appear to induce gastritis or ulcers at moderate doses.

Steamed ginger extract has been suggested as an external remedy for skin. According to Komazaki *et al.* (1986), shogaol and zingerol from ginger have excellent preventive effects against skin flushing and roughening caused by sunburn, razor rash, and inflammation. A mixture of *Citrus sunki* and ginger extracts exhibited antioxidant and anti-aging effects by removing superoxide anions, promoting skin cell proliferation and collagen neo-synthesis, and decreasing the secretion of cytokines generated by oxidative stress. Kim *et al.* (2012) reported on the potential of SDGE for dermal applications; however, SDGE has not been investigated for its ability to cause dermal irritation.

In this study, no abnormal clinical signs attributable to SDGE were detected in any of the tested rabbits. In the dermal irritation test, erythema, eschar, and edema formation were observed 24 h after SDGE treatment, but the skin returned to normal after 72 h. SDGE had a dermal PII of 0.0, classifying it as a non-irritant. These acute oral toxicity and dermal sensitization results suggest that SDGE is non-toxic and non-irritating to skin, indicating that it can be used in pharmaceutical and dermal applications with no serious toxic effects at moderate doses.

The results of this study suggest that SDGE is non-toxic in rats; therefore, it is likely to be safe for clinical use. The sensitization level of SDGE in rabbits was classified as non-irritating when applied to skin, indicating that it can be used in dermal formulations and pharmaceutical applications with no serious toxic effects at moderate doses.

Conflict of interest: The authors declare no conflict of interest.

REFERENCES

- Ali, B.H., G. Blunden, M.O. Tanira, and A. Nemmar (2008). Some phytochemical, pharmacological and toxicological properties of ginger (*Zingiber officinale* Roscoe): A review of recent research. *Food Chem. Toxicol.* 46: 409-420.
- Al-Yahya, M. (1989). Gastroprotective activity of ginger *Zingiber officinale* Rosc. in albino rats. *Am. J. Chin. Med.* 17: 51-56.
- Anonymous (2003). *Zingiberis rhizome*. In: ESCOP Monographs. Thieme Press Stuttgart, New York, pp. 547-553.
- Bae, J.-S. and T.H. Kim (2011). Pancreatic lipase inhibitory and antioxidant activities of *Zingiber officinale* extracts. *Korean J. Food Preserv.* 18: 390-396.
- Boone, S.A. and K.M. Shields (2005). Treating pregnancy-related nausea and vomiting with ginger. *Ann. Pharmacother.* 39: 1710-1713.
- Cheng, Y.-T., C.-H. Wu, C.-Y. Ho, and G.-C. Yen (2013). Catechin protects against ketoprofen-induced oxidative damage of the gastric mucosa by up-regulating Nrf2 *in vitro* and *in vivo*. *J. Nutr. Biochem.* 24: 475-483.
- Cheng, X.L., Q. Liu, Y.B. Peng, L.W. Qi, and P. Li (2011). Steamed ginger (*Zingiber officinale*): Changed chemical profile and increased anticancer potential. *Food Chem.* 129: 1785-1792.
- Choi, J.-S., J.N. Moon, W.S. Moon, E.J. Cheon, J.W. Kim, and M.R. Kim (2015). Acute dermal and ocular irritation test of rice bran supercritical CO₂ extract (RB-SCE) and skin sensitivity test of test essence product with 0.5% RB-SCE. *Toxicol. Environ. Health Sci.* 7: 65-72.
- Choi, W.C., I.C. Jung, J.S. Lim, S.H. Kim, and S.R. Lee (2012). Single oral dose toxicity test of ACM (added Chongmyung-tan) in Sprague-Dawley rat. *J. Orient. Neuropsychiatry* 23: 121-128.
- Chrubasik, S., M.H. Pittler, and B.D. Roufogalis (2005). *Zingiberis rhizoma*: a comprehensive review on the ginger effect and efficacy profiles. *Phytomedicine* 12: 684-701.
- Chun Y.-G. and H.-Y. Chung (2011). Quality properties of fermented gingers. *Korean J. Food Sci. Technol.* 43: 249-254.
- Dourish, C.T. (1987). Effects of drugs on spontaneous motor activity. In: Greenshaw, A.J. and C.T. Dourish, Editors. *Experimental Psychopharmacology*, Humana Press, Clifton, pp. 325-334.
- Draize, J.H., G. Woodard and H.O. Calvery (1944). Methods for the study of irritation and toxicity of substances applied topically to the skin and mucous membranes. *J. Pharmacol. Exp. Ther.* 82: 377-390.
- Fahmy, S.R., M.A. Amer, and M.H. Al-killidar (2015). Ameliorative effect of the sea cucumber *Holothuria arenicola* extract against gastric ulcer in rats. *JOBAS* 72: 16-25.
- Flecknell, P. A. (1996). *Laboratory Animal Anesthesia*, 2nd Ed., Harcourt Brace and Company, London, p. 269.
- Globally Harmonized System of Classification and Labelling of Chemicals (2011). New York and Geneva, United Nations.
- Irwin, S. (1968). Comprehensive observational assessment: Ia. A systemic, quantitative procedure for assessing the behavioral and physiological state of the mouse. *Psychopharmacologia* 13: 222-257.

- Jung, K. and C.-S. Park(2013).Antioxidative and antimicrobial activities of juice from garlic, ginger, and onion. *Korean J. Food Preserv.*20: 134-139.
- Jung, Y.-S. S.J.Park, J.H. Park, K.H. Jhee, I.S.Lee, andS.A.Yang(2012).Effects of ethanol extracts from *Zingiber officinale* Rosc., *Curcuma longa* L.,and *Curcuma aromatica* Salisb. on acetylcholinesterase and antioxidant activities as well as GABA contents. *J. Korean Soc. Food Sci. Nutr.*41: 1395-1401.
- Kim, H.K., B.Y. Kim,and Y.T. Ham(2012). Cosmetic composition containing steamed ginger extracts for skin-whitening and method of preparing thereof. KP 101145083.
- Kim, K.T. (2011)Development of value-added ginger products for industrial application and export. Ministry for Food, Agriculture, Forestry and Fisheries, Seoul, Korea.
- Kim, K.T.,Y.C.Lee, S.S.Kim, H.D.Hong, Y.C.Kim, S.Y.Choi, Y.K.Lee, J.H.Rho, J.W.Jo, M.H.Lee(2013a). Pharmaceutical composition with enhanced antioxidant activity comprising the extract of aged ginger. KP 10-2013-0115949.
- Kim, K.T.,Y.C.Lee, S.S.Kim, H.D.Hong, Y.C.Kim, S.Y.Choi, Y.K.Lee, J.H.Rho, J.W.Jo, M.H.Lee(2013b).Composition comprising the extract of aged ginger for preventing and treating liver disease. KP 1020130115945.
- Kim, S.-J., Y.-G. Kim, and K.-Y. Park(2012).Inhibitory effects of ginger and processed (beopje) ginger extracts on HCl-ethanol induced gastritis in rats. *J. Korean Soc. Food Sci. Nutr.*41: 1528-1533.
- Kim, S.-J., S.-H.Kim, Y.-I.Lim, Y.-G.Kim, andK.-Y. Park(2014).Inhibitory effects of ginger and beopje ginger on DSS-induced colitis in mice. *J. Korean Soc. Food Sci. Nutr.*43: 477-484.
- Komazaki, H., T.Magara,T. Ikeda,T. Hirao, H.Watabe,E. Sato (1986).External remedy for skin. JP61263909.
- Koo S.-W.andK.-W. Lee (2012).The Protective effect of ginger aqueous extracts on CCl₄-induced hepatic damage in mice. *J. Vet. Clin.*29:441 – 446.
- Korea Food and Drug Administration (2009). TestingGuidelines for Safety Evaluation of Drugs. Notification No.2009-116.
- Korea Food and Drug Administration(2012). Toxicity teststandard of drug etc. Notification No. 2012-86.
- Kwak, J.S.,J.E. Paek, S. Jeong, J. Kim, J.Y. Kim, and O. Kwon (2014).Systematic review of the effect of dried ginger powder on improvement of nausea and vomiting associated with early pregnancy or motion sickness. *J. Nutr. Health*47:45-50.
- Lee, M.-H., K.-T. Kim, and K.-H.Lee(2012).Quality characteristics of ginger (*Zingiber officinale* Roscoe) as the ripening periods. *J. Fd. Hyg. Safety* 27: 479-486.
- Lee, M.-H., K.-H.Lee, K.-T. Kim, andS.-S. Kim(2012).Antimicrobial activity of ginger (*Zingiber officinale* Roscoe) oleoresin by supercritical fluid extraction. *J. Fd. Hyg. Safety*27: 109-116.
- Marcus, D.M. and W.R.Snodgrass(2005).Do no harm: avoidance of herbal medicines during pregnancy. *Obstet. Gynecol.*105: 1119-1122.
- Mascol, N., R.Jain, S.C. Jaw, and F. Capasso(1989). Ethnopharmacologic investigation of ginger (*Zingiber officinale*). *J. Ethnopharmacol.*27:129- 140.
- Organization for Economic Co-Operation and Development(1981).OECD Acute dermal irritation/corrosion. In *OECDGuidelines for Testing of Chemicals*. Section 4, no. 404.OECD, Paris.
- Organization for Economic Co-Operation and Development(2001).OECD Guideline (423) for testingof chemicals – acute oral toxicity-acute toxic classmethod (Paris, France).
- Seo, B.I., B.H.Byun, S.S. Shin,and B.H. Kim (2003).Herbal Food, Bethel Pub. Co, Daegu, Korea, pp. 102-104, pp. 166-168, pp. 190-192.
- Shin, W.S. (2008).Comparison of physicochemical characterization of black ginseng (*Ginseng Radix nigra*). Korea University. Master thesis.
- Sung, T.H., I.S.Um, O.S. Heo,and M.R. Kim (2003).Quality characteristics of ginger tea. *J. Korean Soc. Food Sci. Nutr.*32:47-51.
- Weidner, M.S. andK.Sigwart(2000).The safety of a ginger extract in the rat. *J. Ethnopharmacol.*73: 513-520.
- Wilkinson, J.M.(2000).Effect of ginger tea on the fetal development of Sprague-Dawley rats. *Reprod. Toxicol.*14: 507-512.
- Wu, H., D. Ye, Y.Bai, andY. Zhao(1990). Effect of dry ginger and roasted ginger on experimental gastric ulcers in rats. *Zhongguo Zhong Yao Za Zhi*15:278–280.
- Yang, C.B., K.Y. Yoon, S.R. Shin,and S.J. Lee (2014).Black doraji extract and its manufacturing method. KP1013523730000.
- Yang, W.K., C.S. Jung, K.W.Jung, J.W. Kim,and E.B. Lee (1992).Antigastric and antiulcerative action of the extract of *ZingiberRhizoma*. *Yakhak Hoeji*36: 173-179.